

British Thoracic Society guideline for advanced diagnostic and therapeutic flexible bronchoscopy in adults

I A Du Rand,¹ P V Barber,² J Goldring,³ R A Lewis,⁴ S Mandal,⁵ M Munavvar,⁶ R C Rintoul,⁷ P L Shah,⁸ S Singh,⁹ M G Slade,⁷ A Woolley,⁴ on behalf of the British Thoracic Society Interventional Bronchoscopy Guideline Group

► An additional appendix 4 is published online only. To view this file please visit the journal online (<http://thorax.bmj.com>).

¹Queen Elizabeth Hospital, Birmingham, UK

²North West Lung Centre, University Hospital of South Manchester, Manchester, UK

³Royal Free Hospital, London, UK

⁴Worcestershire Royal Hospital, Worcester, UK

⁵Lane-Fox Unit, St Thomas' Hospital, London, UK

⁶Lancashire Teaching Hospitals NHS Trust, Preston, UK

⁷Department of Thoracic Oncology, Papworth Hospital, Cambridge, UK

⁸Department of Respiratory Medicine at Royal Brompton Hospital, London, Chelsea & Westminster Hospital, and Imperial College, London, UK

⁹Chelsea and Westminster Hospital, London, UK

Correspondence to

Dr Ingrid A Du Rand, The British Thoracic Society, 17 Doughty Street, London WC1N 2PL, UK; ingrid.durand@nhs.net

Membership of the Committee with their conflicts of interest are shown in Appendix 1 and a list of stakeholders is given in Appendix 5.

Received 30 June 2011

Accepted 4 July 2011

SUMMARY OF RECOMMENDATIONS

Diagnosis of mediastinal/hilar lymph nodes and peribronchial masses

Conventional transbronchial fine needle aspiration (TBNA)

- B ► Conventional transbronchial needle aspiration (TBNA) is a safe technique and should be used to sample mediastinal and hilar lymphadenopathy during initial diagnostic bronchoscopy where a pre-procedure CT scan has demonstrated significant adenopathy.
- Conventional TBNA is a safe technique for sampling hilar and mediastinal lymph nodes in cases of suspected sarcoidosis and may be used in conjunction with endobronchial and transbronchial biopsies.
- ✓ ► Depending upon the clinical setting, a non-diagnostic conventional TBNA result may warrant further investigation. Real-time endobronchial ultrasound-guided TBNA (EBUS-TBNA) or surgical lymph node sampling should be considered.

Endobronchial ultrasound-guided transbronchial fine needle aspiration (EBUS-TBNA)

- B ► EBUS-TBNA is a safe and effective technique for the assessment of hilar and mediastinal lymph nodes in cases of confirmed or suspected lung cancer.
- EBUS-TBNA is a safe and effective technique for sampling hilar and mediastinal lymph nodes in cases of suspected sarcoidosis and may be used in conjunction with endobronchial and transbronchial biopsies.
- D ► EBUS-TBNA is a safe and effective technique for sampling paratracheal and peribronchial intraparenchymal lung masses.
- At present there is insufficient evidence to recommend EBUS-TBNA for routine use in the diagnosis of lymphoma.
- ✓ ► In cases where EBUS-TBNA results are negative for malignancy, a confirmatory surgical biopsy should be performed where appropriate.

Therapeutic procedures for malignant disease

Malignant airway obstruction

1. Endobronchial debulking of tumours

- D ► In patients with central airway obstruction (CAO) due to intraluminal tumour, endobronchial tumour debulking should be considered.
- ✓ ► When undertaking endobronchial debulking of tumours, a laryngeal mask or uncuffed endotracheal tube is recommended to achieve airway control.

2. Endobronchial electrocautery or diathermy

- D ► Endobronchial electrocautery may be considered for use with curative intent in benign disease of the airway including incising web-like stenosis, benign tumours and granulation tissue. It may also be considered for primary treatment of early stage non-invasive lung cancer.
- Endobronchial electrocautery may be considered for palliation of malignant CAO, with or without critical airway narrowing.
- ✓ ► When undertaking snare resection, intermittent bursts of electrocautery of not more than 2 s duration should be used while carefully closing the snare until resistance is felt.
- Avoid an Fio₂ of >0.4 when undertaking electrocautery to reduce the risk of airway fire.

3. Argon plasma coagulation (APC)

- D ► APC may be considered for the debulking of obstructing endobronchial tumour.
- APC may be considered for tumour debulking in patients without acute critical airway narrowing.
- APC may be considered for the treatment of haemoptysis in patients with endobronchial abnormalities.

4. Thermal laser

- D ► In patients with CAO due to intraluminal tumour, relief of obstruction using Nd-YAG laser may be considered.
- ✓ ► The power setting should be limited to 40 W

5. Cryotherapy and cryoextraction

- B ► Cryobiopsy may be considered for diagnostic endobronchial tissue sampling to provide large-volume specimens without crush artefact.
- D ► Cryotherapy may be considered for tumour debulking in patients without critical airway narrowing.
- Cryorecanalisation/cryoextraction may be considered for tumour debulking.

6. Photodynamic therapy (PDT)

- D ► PDT may be considered for tumour debulking in patients without critical airway narrowing.
- ✓ ► The technique should be available for carefully selected patients on a regional basis.

7. Brachytherapy

- C ► Brachytherapy should not be used first-line in preference to external beam radiotherapy for the palliation of lung cancer.
- D ► Brachytherapy should be considered for the palliation of haemoptysis or CAO in locally advanced central lung cancer.

Airway support with stents

- D ► The use of self-expanding metallic stents may be considered for the treatment of malignant CAO due to extrinsic disease.
- Self-expanding metallic stents may be used to maintain airway patency following endobronchial debulking techniques.
- Self-expanding metallic stents can be used to restore or maintain airway patency in conjunction with other treatments such as external beam radiotherapy.

- √ ▶ Patients require careful specialist follow-up after stent insertion.
- ▶ Stents should be used with caution in non-malignant disease, considering their long-term complications. Self-expanding metallic stents may be difficult to remove following long-term placement.
- ▶ Self-expanding metallic stents should only be used in benign disease after all other therapeutic options have been exhausted.
- ▶ A risk-benefit assessment should be performed, incorporating immediate and long-term implications, prior to selecting any particular type of stent.

Treatment with curative intent for early lung cancer

- C ▶ Fractionated brachytherapy should also be considered for the curative treatment of early central lung cancer, especially if performance or cardiorespiratory status precludes surgery or radical external beam radiotherapy. The success of brachytherapy for radical treatments requires accurate local staging to exclude extrabronchial tumour extension.
- D ▶ PDT can be considered for the curative treatment of early central lung cancer, especially for tumours 1 cm or less in diameter and provided there is no imaging evidence of extrabronchial involvement.
- ▶ PDT can be considered for the curative treatment of recurrent lung cancer where there is localised endobronchial disease in patients who are not fit for surgery or radical radiotherapy.

Emerging applications for flexible bronchoscopy

Electromagnetic navigation bronchoscopy

- D ▶ Electromagnetic bronchoscopy may be considered for the biopsy of peripheral lesions or to guide TBNA for sampling mediastinal lymph nodes.

Endobronchial valves in emphysema

- B ▶ Endobronchial valves may be considered in the treatment of selected patients with severe emphysema and hyperinflation with heterogeneous disease in the absence of significant collateral ventilation or who have a complete fissure on CT scanning.

- √ ▶ Patients should be enrolled into clinical trials until more robust data of clinical benefit is available.

Bronchial thermoplasty in asthma

- A ▶ Bronchial thermoplasty is a possible treatment option in selected patients with severe persistent asthma already on maximal therapy, although its place in the treatment of asthma remains to be established.
- √ ▶ Long-term safety and efficacy remain unclear. Hence, treatment should be limited to a few specialist centres in carefully selected patients. Longer-term follow-up of treated patients is recommended.

INTRODUCTION

Clinical context and need for a guideline

Interventional bronchoscopy has rapidly evolved in recent years. The field includes the use of more complex diagnostic procedures such as endobronchial ultrasound, the use of bronchoscopic interventions for the relief of central airway obstruction (CAO) due to malignancy and, more recently, the development of therapeutic interventions for non-malignant disease.¹ Many practitioners may feel that this is a highly specialist field and that the techniques are experimental, only for tertiary centres. Perhaps they feel that they do not have the expertise to undertake these procedures. The fact is that some of these techniques such as transbronchial needle aspiration (TBNA) really should be part of every bronchoscopist's practice. Others such as endobronchial ultrasound (EBUS) are rapidly becoming standard practice and should be available to all patients, and some such as bronchial thermoplasty and airway valves are yet to establish their role in routine practice. There are also a large variety of methods of tumour debulking, and it is clearly not easy for a practitioner outside the field to know what are the indications, contraindications, potential benefits and complications of each technique, or which technique to consider learning. This guideline therefore aims to help all those who undertake flexible bronchoscopy to understand more about this important and rapidly developing area.

In August 2007 the Standards of Care Committee of the British Thoracic Society (BTS) invited the Interventional Pulmonology Specialist Advisory Group of the BTS to produce an evidence-based update of the guideline on bronchoscopy and agreed this should now include interventional bronchoscopy. The Working Party decided to start with this new guideline on interventional bronchoscopy.

Target audience of the guideline

This guideline is aimed primarily at practitioners within the UK but may be of relevance to other healthcare systems. It is intended to inform those who undertake or intend to undertake the procedures within the guideline, and also to inform others as

to what may be available for patients under their care and the indications, likely response and complications of such procedures. Not all of the procedures may be available in all areas, including some tumour debulking procedures, but at least one of the tumour debulking modalities should be available in each cancer network.

Scope of the guideline

This guideline was formulated following consultation with stakeholders from the medical and nursing professions, patient groups and healthcare management. Advanced diagnostic and therapeutic procedures in adults using a flexible bronchoscope are included in the guideline.

Topics covered in the guideline

- ▶ Transbronchial needle aspiration (TBNA) and endobronchial ultrasound-guided (EBUS) TBNA
- ▶ Electrocautery/diathermy
- ▶ Argon plasma coagulation (APC)
- ▶ Laser
- ▶ Cryotherapy
- ▶ Cryoextraction
- ▶ Photodynamic therapy (PDT)
- ▶ Brachytherapy
- ▶ Tracheobronchial stents
- ▶ Electromagnetic navigation bronchoscopy (ENB)
- ▶ Endobronchial valves for emphysema
- ▶ Bronchial thermoplasty for asthma

Topics not covered in the guideline

- ▶ Rigid bronchoscopy
- ▶ Autofluorescence bronchoscopy

Rigid or flexible bronchoscopy for interventional procedures?

This guideline covers interventional procedures performed using flexible bronchoscopy. In many units, however, rigid bronchoscopy alone would be used for such procedures. Most UK respiratory physicians lack training in rigid bronchoscopy, and most

bronchoscopy units outside thoracic surgery centres do not have ready access to rigid bronchoscopy as a back-up for, or as an alternative to, flexible bronchoscopy.

The main advantages of flexible bronchoscopy are:

1. It is widely available
2. The majority of respiratory physicians are trained to use flexible bronchoscopy
3. It does not require a general anaesthetic
4. It provides access to more distal airways and good access to the upper lobe bronchi

The main advantages of rigid bronchoscopy are:

1. A general anaesthetic is more comfortable for the patient
2. It allows control of ventilation and oxygenation during interventional procedures
3. It permits the removal of large volumes of tumour
4. It provides more control in cases of massive haemoptysis
5. It permits silicon stent insertion
6. Obstructing airway lesions can be cored out
7. Large centrally-placed foreign bodies can be removed

Most interventional procedures, however, can be undertaken via flexible or rigid bronchoscopy, including removal of many foreign bodies, metallic stent insertion and tumour debulking with diathermy, argon plasma, cryoextraction and photodynamic therapy (PDT). Although thermal lasers can be used with either scope, most practitioners of this technique prefer to use rigid bronchoscopy. Silicone and Y-stents are inserted via rigid bronchoscopy.

METHODOLOGY

This guideline is based on the best available evidence. The methodology used to write the guideline adheres strictly to the criteria as set by the AGREE collaboration in the document, which is available online <http://www.agreecollaboration.org/1/agreeguide/>.

Clinical questions and literature search

Clinical questions were gathered in the PICOT (Patient, Intervention, Control, Outcome and Time) format to define the scope of the guideline and inform the literature search.

Systematic electronic database searches were conducted in order to identify potentially relevant studies for inclusion in the guideline. For each topic area the following databases were searched: Ovid MEDLINE (from 1988) (including MEDLINE In Process), Ovid EMBASE (from 1988), Ovid CINAHL (from 1982) and the Cochrane Library (from 1992) (including the Cochrane Database of Systematic Reviews, the Database of Abstracts of Reviews of Effects, the Cochrane Central Register of Controlled Trials, the Health Technology Assessment database and the NHS Economic Evaluation Database).

The searches were first run in January 2008 and updated in September 2010. Searches were saved and run on a monthly basis to identify newly published literature to date. Searches included a combination of indexed terms and free text terms and were limited to English language publications only. The initial search identified 3751 potential papers.

Appraisal of the literature

Appraisal was performed using the criteria stipulated by the AGREE collaboration. Each paper was appraised by a pair of reviewers. One individual (IDR) read the title and abstract of each article retrieved by the literature searches and decided whether the paper was definitely relevant, possibly relevant or not relevant to the project. Criteria formulated for categorising the abstracts into these three groups were:

- ▶ Whether the study addressed the clinical question.
- ▶ Whether the appropriate study type was used to produce the best evidence to answer the clinical question.
- ▶ Abstract was in English.
- ▶ Studies where exclusively rigid bronchoscopy was used were not evaluated.
- ▶ Abstracts were not rejected on the basis of the journal of publication, country in which the research was performed or published nor the date of publication.

The full paper was obtained for all relevant or possibly relevant abstracts and allocated to the relevant section(s) which were broadly grouped as argon plasma, brachytherapy, cryotherapy, diathermy, EBUS, TBNA, endobronchial valves, general interventional bronchoscopy, laser, photodynamic therapy, stents, thermoplasty and virtual bronchoscopy with electromagnetic navigation.

The first screening process identified 1022 of the initial 3751 reference abstracts to be definitely or possibly relevant to the guideline. Two guideline reviewers independently reviewed the abstracts to identify papers to be appraised for the guideline.

Three hundred and eighty-seven papers were critically appraised. The two leads for each section independently appraised each paper assigned to them using the Scottish Intercollegiate Guidelines Network (SIGN) critical appraisal checklists. A web-based guideline development tool (<http://www.bronchoscopy-guideline.org>) enabled each pair of reviewers to collaborate online. The reliability of the evidence in each individual study was graded using the SIGN critical appraisal check lists and is shown in the evidence tables (+++, + or –). The body of evidence for each recommendation was summarised into evidence statements and graded using the SIGN grading system (see table 1). Disagreements were resolved by discussion with the section partner.

Considered judgement and grading of evidence

The Guideline Group used the online-derived evidence tables to judge the body of evidence and grade recommendations for this guideline. Evidence tables are shown in online Appendix 4 available online. Where evidence was lacking to answer the formulated clinical questions, expert opinions were obtained for formal consensus statements using the Delphi method. The following were considered in grading of the recommendations:

- ▶ The available volume of the body evidence.
- ▶ How applicable the obtained evidence was in making recommendations for the defined target audience of this guideline.

Table 1 Revised grading system for recommendations in evidence based guidelines

Grade	Evidence
1++	High quality meta-analyses, systematic reviews of RCTs, or RCTs with a very low risk of bias
1+	Well conducted meta-analyses, systematic reviews of RCTs, or RCTs with a low risk of bias
1–	Meta-analyses, systematic reviews or RCTs, or RCTs with a high risk of bias
2++	High quality systematic reviews of case-control or cohort studies or High quality case-control or cohort studies with a very low risk of confounding, bias or chance and a high probability that the relationship is causal
2+	Well conducted case-control or cohort studies with a low risk of confounding, bias or chance and a moderate probability that the relationship is causal
2–	Case-control or cohort studies with a high risk of confounding, bias or chance and a significant risk that the relationship is not causal
3	Non-analytic studies, for example, case reports, case series
4	Expert opinion

RCT, randomised controlled trial.

- ▶ Whether the evidence was generalisable to the target population for the guideline.
- ▶ Whether there was a clear consistency in the evidence obtained to support recommendations.
- ▶ What the implications of recommendations will be on clinical practice in terms of resources and skilled expertise.
- ▶ Cost-effectiveness was not reviewed in detail as in-depth economic analysis of recommendations fall beyond the scope of this guideline.

Recommendations were graded from A to D as indicated by the strength of the evidence as shown in table 2. Important practical points lacking any research evidence were highlighted as ‘Good Practice Points’ (GPP).

Drafting of the guideline

The Guideline Committee corresponded regularly by email and meetings of the full group were held in December 2007, June 2008, December 2008, March 2009, June 2009 and October 2009. The guideline was discussed at an open session at the BTS Winter Conference in December 2009. A revised draft guideline document was circulated to all the relevant stakeholders for consultation in May 2010 followed by a period of online consultation. The BTS Standards of Care Committee reviewed the draft guideline in July 2010. Further revision was made in September 2010 following the incorporation of suggestions by international experts in interventional bronchoscopy. The guideline was reviewed by the BTS Standards of Care Committee in November 2010 and submitted for publication.

The Guideline Group members adhered to the BTS policy for the Declaration of Interests and, where appropriate, specific interests are declared in Appendix 1.

The guideline will be reviewed and updated in 2015.

Audit, research and training recommendations

Audit

- ▶ All those undertaking any interventional procedure are advised to maintain records of each procedure including indication, outcome and complications for audit purposes.
- ▶ It is recommended that a database should be kept of all those in the UK undertaking interventional procedures and numbers being treated.
- ▶ The database should include details of current training in interventional procedures available in the UK.

Research

- ▶ A randomised controlled trial (RCT) comparing symptom relief and survival in patients with malignant CAO receiving

airway intervention in combination with conventional anticancer therapy versus conventional anticancer therapy alone.

- ▶ An RCT comparing EBUS with surgical staging of the mediastinum in lung cancer.
- ▶ An RCT comparing EBUS-TBNA with standard bronchoscopic techniques for the diagnosis of sarcoidosis.
- ▶ An RCT comparing outcomes including quality of life of treatment by debulking for CAO followed by conventional anticancer treatment with anticancer treatment alone.
- ▶ Defining the population or phenotype of disease that benefits from the bronchoscopic lung volume reduction techniques available.
- ▶ Further RCTs on the techniques available for bronchoscopic lung volume reduction with improved patient selection.
- ▶ Longer-term evaluation of safety and efficacy of bronchial thermoplasty.

Recommended standards of care based on the recommendations in this guideline can be found on the BTS website at: <http://www.brit-thoracic.org.uk/>.

Training

It is clear from a survey of respiratory trainees in the UK that, by the final year of training, few consider themselves to be competent to undertake interventional diagnostic or therapeutic procedures; 36% felt competent to undertake simple TBNA but only 2.8% felt competent to undertake EBUS-TBNA or endobronchial diathermy.² To be competent in any specialised technique it is useful to have attended a course and undertaken the procedure on a model, but it is also necessary to have received experience in a centre undertaking the procedure and also to have hands-on experience. Evidence on training requirements is sparse.

There are published recommendations for training by the American College of Chest Physicians³ and also in the ERS/ATS statement on interventional pulmonology.⁴ The Guideline Group has decided not to quote specific numbers of procedures required to be performed before an individual is deemed competent as these numbers are usually arbitrary. Individuals have different learning curves and hence focus should be towards monitoring an individual’s performance and outcomes.⁵ Standards for particular procedures need to be determined and agreed. These can then be used for outcome-based assessment of competency.

DIAGNOSIS OF MEDIASTINAL/HILAR LYMPH NODES AND PERIBRONCHIAL MASSES

Conventional TBNA

Principles

Transbronchial lymph node sampling can be used both for diagnosis and for staging of lung cancer and can be performed at initial diagnostic bronchoscopy.

TBNA entails inserting a fine (usually 19–22 gauge) needle through the wall of the airway into a lymph node in order to obtain a specimen for cytological, histological or microbiological analysis. The technique can also be used to sample parenchymal lung masses that lie adjacent to the trachea or major airways. The procedure can be performed with or without the use of ultrasound guidance.

Technique

In conventional TBNA a needle is passed through the working channel of a standard bronchoscope to puncture the airway wall at the site of the target lymph node or lung mass, whose

Table 2 Grades of recommendations

Grade	Type of evidence
A	At least one meta-analysis, systematic review or RCT rated as 1++ and directly applicable to the target population <i>or</i> A systematic review of RCTs or a body of evidence consisting principally of studies rated as 1+ directly applicable to the target population and demonstrating overall consistency of results
B	A body of evidence including studies rated as 2++ directly applicable to the target population and demonstrating overall consistency of results <i>or</i> Extrapolated evidence from studies rated as 1++ or 1+
C	A body of evidence including studies rated as 2+ directly applicable to the target population and demonstrating overall consistency of results <i>or</i> Extrapolated evidence from studies rated as 2++
D	Evidence level 3 or 4 <i>or</i> Extrapolated evidence from studies rated as 2+
√	Important practical points for which there is no research evidence nor is there likely to be any research evidence. The Guideline Committee wishes to emphasise these as Good Practice Points.

RCT, randomised controlled trial.

position is determined from study of a pre-procedure CT. Virtual bronchoscopy using CT reconstructions has recently been described and can be used to help identify suitable positions for TBNA. Lymph nodes stations that can be accessed in this way are 2R, 2L, 3P, 4R, 4L, 7, 10R, 10L, 11R and 11L (figure 1).

Ultrasound guidance may be used to locate lymph nodes for TBNA. In early descriptions a radial ultrasound miniprobe introduced through the working channel of a conventional bronchoscope was used to locate lymph nodes. The miniprobe was then removed and a TBNA needle was introduced to puncture the node at the predetermined position. This technique did not allow for real-time ultrasound visualisation of the TBNA. More recently, real-time EBUS-TBNA has been described which involves use of a convex array linear ultrasound bronchoscope. The use of real-time ultrasound imaging during TBNA allows specific nodes to be targeted and permits accurate biopsy of multiple lymph node stations when necessary for staging. Lymph nodes as small as 4 mm in the short axis have been sampled.

The technique of TBNA is simple. Diagnostic yield is dependent upon operator experience, the position and the size of the lymph node. The use of rapid on-site cytopathology improves yield. A guide on how to perform TBNA is available in Appendix 2.

Indications

TBNA is mainly used to sample hilar and mediastinal lymph nodes. It can also be used to sample paratracheal and peribronchial lung masses.

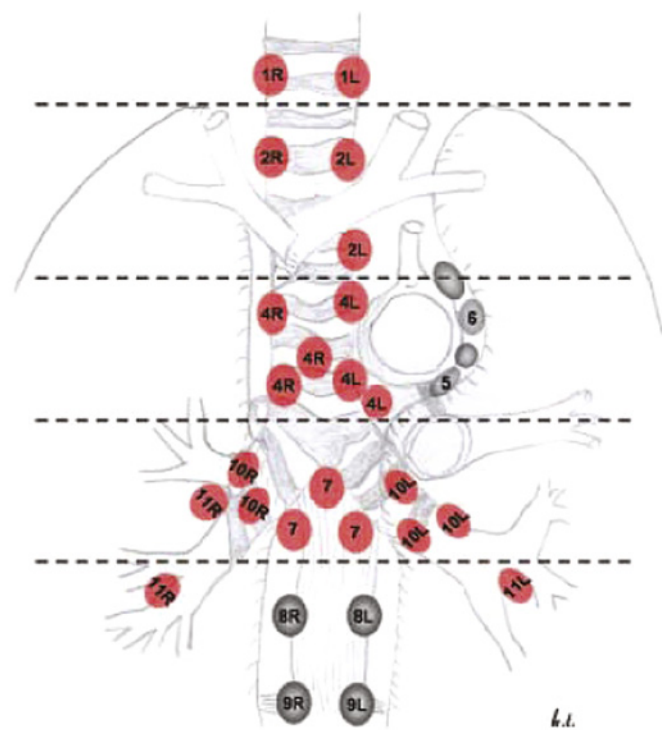


Figure 1 Lymph node stations accessible by transbronchial fine needle aspiration (TBNA) are shown in red. Precise localisation of lymph nodes for TBNA may be assisted by real-time endobronchial ultrasound guidance. Nodes that cannot be sampled by TBNA are shown in dark grey. The dotted lines indicate anatomical borders that are important for identification of the different lymph node stations using endobronchial ultrasound. Station 3a/p nodes are not indicated on this image. Stations 5 and 6 nodes may be seen during endobronchial ultrasound but sampling is usually not possible due to the interposition of the great vessels. Figure reproduced from Tournoy *et al*⁶ with permission of the publishers.

Complications

Conventional (non-ultrasound-guided) TBNA is safe with few reported complications. In a meta-analysis by Holty *et al* the pooled complication rate was 0.3%.⁷ The complications most commonly reported are pneumomediastinum and pneumothorax, minor and self-limiting bleeding and puncture of adjacent structures.

Evidence

The majority of papers on conventional TBNA are case series. One meta-analysis by Holty *et al* has been reported.⁷ The reported sensitivities for this approach vary considerably. In their analysis Holty *et al* divided studies according to whether or not they had surgically confirmed all TBNA results and enrolled at least 10 patients with and without mediastinal metastasis.⁷ In six studies that met these entry criteria, pooled sensitivity and specificity for diagnosis of malignancy were 39% (95% CI 17% to 61%) and 99% (95% CI 96% to 100%), respectively. However, the prevalence of mediastinal metastases in these studies was only 34%. Analysis of another group of studies in the review by Holty *et al* in which the prevalence of mediastinal metastases was 81% had a pooled sensitivity for the detection of malignancy of 78% (95% CI 71% to 84%).⁷ A similar figure was reported by Detterbeck *et al*.⁸ In their review of the literature they reported a pooled TBNA sensitivity of 78% and specificity of 99%. The prevalence of disease in this pooled analysis was 75%.⁸

Two studies have demonstrated that 5–7 aspirates per node are required before a plateau in diagnostic accuracy is achieved.^{9,10} The success rate is highest in lymph nodes >20 mm in the short axis⁷ and in the station 4R and 7 lymph node locations (figure 1).

Rapid on-site cytology may improve the success rate and reduce the number of needle aspirates and the number of lymph node stations sampled.¹⁰

The role of TBNA in the diagnosis of sarcoidosis has been reported.^{11,12} Considering TBNA alone, the diagnostic yield in stage I disease (61–82%) was higher than in stage II (42–75%). However, most operators use TBNA in this setting in conjunction with endobronchial and transbronchial biopsies and diagnostic yields of around 90% are achievable in stage I and II disease.

Evidence statement

- ▶ Conventional TBNA is a safe technique to sample mediastinal and hilar lymphadenopathy at initial diagnostic bronchoscopy in cases of either suspected malignant involvement or sarcoidosis. (Evidence level 2++)

Recommendations

- ▶ Conventional TBNA is a safe technique and should be used to sample mediastinal and hilar lymphadenopathy at initial diagnostic bronchoscopy where a pre-procedure CT scan has demonstrated adenopathy. (Grade B)
- ▶ Conventional TBNA is a safe technique for sampling hilar and mediastinal lymph nodes in cases of suspected sarcoidosis and may be used in conjunction with endobronchial and transbronchial biopsies. (Grade B)

Good practice points

- ▶ Depending upon the clinical setting, a non-diagnostic conventional TBNA result may warrant further investigation. Real-time EBUS-TBNA or surgical lymph node sampling should be considered. (√)

Endobronchial ultrasound-guided transbronchial needle aspiration (EBUS-TBNA)

EBUS-TBNA provides images of the mediastinal structures immediately surrounding the tracheobronchial tree.

Indications

EBUS-TBNA is mainly used to sample hilar and mediastinal lymph nodes. It can also be used to sample paratracheal and peribronchial lung masses.

Complications

In most centres the procedure is performed under moderate sedation. No advantage has been demonstrated by performing the technique under general anaesthesia.¹⁵ The reported safety profile is excellent. In their meta-analysis, Gu *et al* reported only two complications in 1299 patients (0.15%).¹⁴

Evidence

In 2009, two meta-analyses and one systematic review reported the sensitivity and specificity of EBUS-TBNA. Adams *et al* and Gu *et al* reported that the pooled sensitivity for EBUS-TBNA was 88% (95% CI 70% to 94%) and 0.93 (95% CI 91 to 944), respectively.^{14 15} In their systematic review Varela-Lema *et al* reported that sensitivity for the diagnosis of malignancy ranged from 85% to 100%.¹⁶ In all three reports the specificity was 100%, but this figure is artificial as positive TBNA results were not confirmed by surgical resection. It should be noted, however, that many of the published case series upon which the systematic reviews are based come from a relatively small group of investigators and further experience is needed to see if these results can be widely replicated.

Although in case series the reported sensitivity for the detection of malignancy in mediastinal lymph nodes is similar to that of mediastinoscopy,¹⁷ there are no reported prospective studies comparing the accuracy of EBUS-TBNA and mediastinoscopy for staging of lung cancer.

Tournoy *et al* reported on the sensitivity of EBUS-TBNA for diagnosis of malignancy from intraparenchymal lung masses.¹⁸ In this study of 60 patients they reported a sensitivity of 82% (95% CI 69% to 91%). A similar study by Nakajima *et al* reported a sensitivity of 94% in 35 patients.¹⁹

One US-based study has reported the use of EBUS-TBNA in the diagnosis of lymphoma. In a retrospective review of 25 patients who underwent EBUS-TBNA for suspected lymphoma, 10 of 11 patients with a final diagnosis of lymphoma were correctly identified, giving a sensitivity of 90.9% and a specificity of 100%.²⁰ Despite these impressive results, the applicability of EBUS-TBNA for the diagnosis of lymphoma in the UK is unclear, given that histopathology is often required for the final diagnosis.

Four studies have assessed the clinical usefulness of EBUS-TBNA in the diagnosis of sarcoidosis. In these case series EBUS-TBNA was diagnostic in 88–93% of patients. However, it should be noted that the pre-test probability of a final diagnosis of sarcoidosis in these series was high.^{21–24} At present there is no evidence to indicate that EBUS-TBNA sampling of lymph nodes is any more or less effective for identifying non-caseating granulomas than transbronchial/endobronchial lung biopsies combined with bronchoalveolar lavage. A clinical trial addressing this issue is currently underway (<http://Clinicaltrials.gov/NCT00872612>). At present some operators combine transbronchial biopsies and EBUS-TBNA lymph node sampling during a single procedure.

Evidence statements

- ▶ EBUS-guided TBNA has high sensitivity and specificity for identifying malignancy in mediastinal and hilar lymph nodes in patients with lung cancer. (Evidence level 2++)
- ▶ EBUS-TBNA has high sensitivity for identifying malignancy when used for sampling paratracheal and peribronchial parenchymal lung masses. (Evidence level 3)
- ▶ EBUS-TBNA has a high sensitivity for identifying non-caseating granulomas in hilar and mediastinal lymph nodes in cases of suspected sarcoidosis. (Evidence level 2++)
- ▶ The complication rate of TBNA under EBUS guidance is very low, indicating that it is a safe procedure. (Evidence level: 2++)

Recommendations

- ▶ EBUS-TBNA is a safe and effective technique for the assessment of hilar and mediastinal lymph nodes in cases of confirmed or suspected lung cancer. (Grade B)
- ▶ EBUS-TBNA is a safe and effective technique for sampling paratracheal and peribronchial intraparenchymal lung masses. (Grade D)
- ▶ EBUS-TBNA is a safe and effective technique for sampling hilar and mediastinal lymph nodes in cases of suspected sarcoidosis and may be used in conjunction with endobronchial and transbronchial biopsies. (Grade B)
- ▶ At present there is insufficient evidence to recommend EBUS-TBNA for routine use in the diagnosis of lymphoma. (Grade D)

Good practice point

- ▶ In cases where EBUS-TBNA results are negative for malignancy, a confirmatory surgical biopsy should be performed where appropriate. (√)

THERAPEUTIC PROCEDURES FOR MALIGNANT DISEASE: MALIGNANT AIRWAY OBSTRUCTION

Endobronchial debulking of tumours

Most new diagnoses of lung cancer are made at an advanced disease stage with 50% of patients having involvement of the central airways either due to endobronchial disease, extrinsic compression or both.¹³ Endotracheal or endobronchial obstruction by malignant disease may lead to cough, breathlessness and obstructive pneumonia.

Endobronchial therapy may result in improvement of symptoms and quality of life. There are a number of treatment options available for relieving such symptoms including external beam radiotherapy. However, endobronchial debulking of tumours using rigid and flexible bronchoscopy is commonly used in some centres, especially when such techniques are readily available. There is a need to know the frequency of use of the various debulking techniques, and for more studies to compare the response to other forms of symptom palliation including external beam radiotherapy.

Rigid bronchoscopic procedures under general anaesthesia combine the ability to maintain adequate ventilation, to remove large volume tumour and safely control large volume haemorrhage, but the widespread availability of, and increasing experience in, flexible bronchoscopy has led to an increasing use of flexible bronchoscopic procedures for debulking.

Available procedures for debulking endobronchial tumours via flexible bronchoscope include:

1. Electrocautery/diathermy
2. Argon plasma coagulation (APC)
3. Thermal laser
4. Cryotherapy

5. Cryoextraction/cryorecanalisation
6. Photodynamic therapy (PDT)
7. Brachytherapy

Some of these procedures offer immediate relief of symptoms and in others the benefit is delayed. Where there is extrinsic compression of the airway, insertion of a stent may be more appropriate. When these procedures are performed, there should be adequate airway control since they carry significant risks of haemorrhage, respiratory failure and cardiac arrhythmias.²⁵ A secure airway such as an endotracheal tube or laryngeal mask should be considered since this allows rapid and repeated insertion of the bronchoscope, high volume suction and the deployment of a balloon bronchial blocker. An example of a malignant airway obstruction flow diagram is shown in Appendix 3.

Recommendation

- ▶ In patients with CAO due to intraluminal tumour, endobronchial tumour debulking should be considered. (Grade D)

Good practice point

- ▶ When undertaking endobronchial debulking of tumours, a laryngeal mask or uncuffed endotracheal tube is recommended to achieve airway control. (√)

Electrocautery or diathermy

Principles

Electrocautery (also known as diathermy) uses high-frequency electric current to cause heating which leads to coagulation at lower temperatures or tissue vaporisation at higher temperatures. The current is delivered endobronchially via a probe, snare or needle knife. The degree of tissue destruction depends on the power used, the duration and surface area of contact, and the density and moisture content of the tissue.²⁶ A monopolar technique is used in the airways. The current passes from the applicator device, through the body to a return electrode usually applied to a limb. Low voltage, low power and high current settings will cause coagulation, while high voltage and low current will cause carbonisation ('cutting'). Most electrocautery devices used via the bronchoscope use a blend of cut and coagulation waveforms.

Technique

The equipment required for electrocautery is a high-frequency electrocautery generator and a selection of devices for endobronchial application. These may include a wire snare, probe, needle knife and 'hot' or punch biopsy forceps. The passage of an uncuffed endotracheal tube over the flexible bronchoscope at the beginning of the procedure can facilitate repeated removal of resected tissue. The initial energy setting (around 20 W) should be tested on normal mucosa before treating the lesion. Duration of treatment will affect the depth of tissue damage. Van Boxem *et al* showed that, at a power setting of 30 W, the depth of tissue necrosis increased with duration of application, from 0.1 mm after 1 s progressively to 1.9 mm after 5 s.²⁷ Longer duration of coagulation (3–5 s) caused damage to underlying cartilage. It is necessary to continuously remove mucus, debris and blood to avoid current leakage.

The probe may be used to vaporise superficial tumours. The snare is useful for debulking large volumes, especially of polypoid tumours. It may be necessary to take a number of separate sections of tumour before the airway is opened up. Removal of large volume tumour from the airway can be achieved in a variety of ways including suction, grasping or

biopsy forceps, or use of a cryoprobe. The knife is particularly useful for resecting benign webs.

Indications

Electrocautery has been used for treating benign and malignant disease, and with both curative and palliative intent. The prospective management of benign stenoses using electrocautery²⁸ is effective. It has also been used for removal of granulation tissue and removal with curative intent of both benign and early stage malignant tumours with a visible distal margin and <3 mm invasion of the bronchial mucosa and no invasion of the cartilage.²⁷ Radiographically occult lung cancer can be treated with bronchoscopic electrocautery. Electrocautery has principally been used for the palliation of malignant CAO. It appears to be as effective in achieving tumour debulking as the neodymium-yttrium-aluminium-garnet (Nd:YAG) laser and can provide immediate relief of symptoms.²⁹

Complications

The main complication of diathermy is bleeding. In the largest series this occurred in 1:56 cases.²⁹ Airway fire has been described.^{30–32} To avoid this complication, a fractional inspired oxygen (FiO₂) of 0.4 or less is recommended, and some groups recommend switching off supplemental oxygen during diathermy use.³³

Careful application of the patient plate and the use of insulated bronchoscopes reduce the risk of current leakage causing burns. Use in patients with pacemakers should be avoided if possible but, if use is unavoidable, guidelines for reducing risk are available from the Medicines and Healthcare products Regulatory Agency (MHRA).³⁴ It is recommended that the skin surface overlying a metallic joint prosthesis be avoided when placing return electrodes for electrocautery.

Evidence

The evidence for palliation of airway obstruction from both primary and metastatic lung tumour comes from case series alone.^{29–31 33 35–38} The results are consistent, with successful outcomes in 39/56 patients,³⁵ 27/32 patients³⁶ and 35/37 patients.³³ A safety study undertaken by Horinouchi *et al*³³ concluded that electrocautery is a safe and reliable procedure when used according to strict guidelines, which include a power output not exceeding 30 W for punch biopsy and snare resection, 20 W for probe, and 10 W for needle knife. To prevent airway fire the authors allowed supplemental oxygen only when electrical current was not being applied.

Evidence statements

- ▶ Endobronchial electrocautery has an acceptable safety profile in experienced hands provided appropriate device settings are employed. (Evidence level 3)
- ▶ Endobronchial electrocautery is effective for endobronchial tumour debulking, with or without critical airway narrowing. (Evidence level 3)
- ▶ Endobronchial electrocautery is effective in the treatment of early stage lung cancer. (Evidence level 3)
- ▶ Endobronchial electrocautery is effective in the treatment of benign tumours and stenoses of the airways. (Evidence level 3)

Recommendations

- ▶ Endobronchial electrocautery may be considered for use with curative intent in benign disease of the airway including incising web-like stenosis, benign tumours and granulation tissue. It may also be considered for primary treatment of early stage non-invasive lung cancer. (Grade D)

- ▶ Endobronchial electrocautery may be considered for palliation of malignant CAO, with or without critical airway narrowing. (Grade D)

Good practice points

- ▶ When undertaking snare resection, intermittent bursts of electrocautery of not more than 2 s duration should be used while carefully closing the snare against resistance. (✓)
- ▶ Avoid an FiO_2 of >0.4 when undertaking electrocautery to reduce the risk of airway fire. (✓)

Argon plasma coagulation (APC)

Principles

APC is a non-contact mode of electrocautery that can be delivered using flexible bronchoscopy. It causes desiccation and coagulation of exophytic endobronchial tumours, and can provide rapid haemostasis when used to treat haemoptysis arising from visible endobronchial lesions.^{39–43}

Technique

The technique requires a suitable high-frequency current generator, a source of argon, a return electrode and a flexible delivery catheter containing a monopolar treatment electrode. The treatment catheter is made from a Teflon tube, typically of 1.5 mm or 2.3 mm in diameter, which contains a thin wire. The wire conducts the high-frequency current to the tip of the catheter where it ends in a tungsten electrode. The computer-controlled high-frequency generator sends high-voltage high-frequency current to the electrode, while argon is delivered along the catheter at a flow rate of 0.3–2.0 l/min. Argon plasma is produced at the tip and emerges from the catheter as a ‘spray’ of coagulating current, which seeks the path of least electrical resistance to the return electrode through the patient. It is recommended that the skin surface overlying a metallic joint prosthesis be avoided when placing return electrodes for APC. As the current passes through the bronchial mucosa, resistance within the tissue leads to heating, coagulation and desiccation. Increasing electrical resistance in the coagulated tissue in turn limits current flow and therefore the depth of coagulation, which is about 2 mm after a 2 s application. This self-limiting effect of APC is a useful feature for endobronchial application, reducing the risk of bronchial perforation.

Indications

APC is principally used for:

- ▶ The treatment of haemoptysis caused by lesions within the central airways.
- ▶ Debulking of exophytic endobronchial tumours, both benign and malignant.
- ▶ Debulking of granulation tissue arising as a complication of tracheobronchial stent insertion.

The published studies of APC do not permit the identification of patients most likely, on clinical or radiological grounds, to benefit from the procedure.

Contraindications

In common with other ablation procedures performed using flexible bronchoscopy, APC should not normally be used for the treatment of lesions causing significant tracheal obstruction unless facilities are immediately available for securing the airway in the event of complications. Such lesions can more safely be treated by flexible bronchoscopy under general anaesthesia with endotracheal intubation or by rigid bronchoscopy. As with laser or electrocautery, APC is contraindicated where there is a requirement for a FiO_2 of >0.4 because of the theoretical risk of

endobronchial fire, although this complication has not been described in the literature. Most modern implantable cardiac pacemakers or defibrillators are compatible with diathermy/APC, but advice should be sought from the patient’s cardiologist prior to the procedure.

Complications

No procedure-related complications were described in the studies of Morice *et al*, Crosta *et al* and Okada *et al*.^{39 41 42} One patient died within 48 h of the procedure but this was ascribed to neutropenic sepsis. In the study by Reichle *et al*, 5/364 patients (1.4%) developed bronchial or tracheal perforations, all of which resolved on treatment.⁴⁰ Three patients developed temporary post-procedural neurological complications and two patients died (myocardial infarction, hypovolaemic shock). The neurological and cardiac complications in these five patients may have been caused by intracardiac gas embolism. This has also been described by Reddy *et al*⁴⁴ who reported three cases of intracardiac gas embolism (two fatal) occurring after APC over a period of 3 years, an estimated incidence of 1.3–2%. All were treated using rigid bronchoscopy and it is not clear whether gas embolism arose as a complication of APC or of jet ventilation. The overall incidence of significant complications appears therefore to be approximately 2%.

Evidence

The use of APC to treat CAO or haemoptysis using flexible bronchoscopy was examined in four retrospective case series involving 123 patients.^{39 41–43} In a much larger retrospective analysis of 364 prospectively collected cases,⁴⁰ rigid bronchoscopy was used in more than 90%, but a flexible bronchoscope was passed through the rigid bronchoscope to deliver the treatment.

The studies used different outcome measures for relief of CAO, retrospectively specified in all except the study by Reichle *et al*.⁴⁰ The outcome measure used for haemoptysis was consistent—namely, non-recurrence during follow-up.

In treating CAO, APC consistently improved symptoms and airway patency in all studies. In the only study with predefined outcomes, APC produced complete or partial success in reopening the treated airway in two-thirds of patients (124/186).⁴⁰ The treatment of haemoptysis was described as being completely successful in 149/150 patients. The evidence is from case series alone but the outcomes are consistent.

Evidence statements

- ▶ APC is effective in the treatment of CAO. (Evidence level 3)
- ▶ APC is effective in the treatment of haemoptysis due to endobronchial disease. (Evidence level 3)
- ▶ APC delivered via flexible bronchoscopy for the treatment of CAO or haemoptysis due to endobronchial lesions has a major complication rate of 2%. (Evidence level 3)

Recommendations

- ▶ APC may be considered for the debulking of obstructing endobronchial tumour. (Grade D)
- ▶ APC may be considered for tumour debulking in patients without acute critical airway narrowing. (Grade D)
- ▶ APC may be considered for the treatment of haemoptysis in patients with endobronchial abnormalities. (Grade D)

Thermal laser

Principles

Laser therapy for the relief of endobronchial obstruction was first described in 1974 using the CO_2 laser. The majority of

publications report use of the Nd-YAG laser. In laser therapy the heat energy from laser light is used to coagulate and vaporise endobronchial tissue.

Technique

The technique can be delivered via rigid or flexible bronchoscopy. Low-power laser is used initially to coagulate tissue to reduce the risk of bleeding. The laser fibre tip should be at least 3 mm from the target tissue to avoid the tissue being vaporised. Continuous suction is used during the procedure to remove smoke from the airways, and continuous inspection of non-obstructed airways is performed to remove any debris and to optimise ventilation. Inspired oxygen is limited to 40% to reduce the risk of airway fire. Laser exposure should be kept to a minimum.

Indications

The main indication for laser therapy is the immediate relief of endobronchial obstruction due to primary lung cancer or metastatic disease.

Complications

Complications include massive haemorrhage (1%), pneumothorax (0.4%) and pneumomediastinum (0.2%).⁴⁵ The peri-procedural death rate is 2–3%.^{46–48} Thermal laser causes more airway scarring and subepithelial fibrosis than other immediate debulking techniques such as diathermy, argon plasma and cryoextraction.⁴⁹ With the Nd-YAG laser the literature suggests that the complication rate can be reduced by limiting the power setting to a maximum of 40 W.⁴⁵

Evidence

Data are almost entirely from case series^{45 50–53} and, although outcome data in many of these series are poorly documented, laser therapy appears to be effective in providing rapid relief of endobronchial obstruction with symptomatic improvement in around 70–80%.^{47 48 54} One-year survival following treatment was around 30%.^{45 46} There is some evidence that outcomes are better if the airway is not totally occluded prior to treatment. Laser therapy has no role in airway occlusion due to extrinsic compression.

Nd-YAG laser is a technique with considerable set-up and maintenance costs. Coulter *et al* and Boxem *et al* reported that electrocautery was as effective as laser in the palliation of endobronchial tumour, but is less expensive.^{55 56}

Evidence statements

- ▶ Nd-YAG laser is effective for endobronchial tumour debulking, with or without critical airway narrowing. (Evidence level 3)
- ▶ There is no role for laser therapy in endobronchial obstruction caused by extrinsic compression. (Evidence level 3)

Recommendation

- ▶ In patients with CAO due to intraluminal tumour, relief of obstruction using Nd-YAG laser may be considered. (Grade D)

Good practice point

- ▶ Limit power setting to 40 W. (✓)

Cryotherapy and cryoextraction

Principles

Cryotherapy uses extreme cold to cause delayed local destruction of tissue. It is applied in cycles of freezing and thawing, causing tissue necrosis.

Technique

Cryotherapy is currently used in two different ways. Standard cryotherapy uses a cryoprobe inserted through the instrument channel of a bronchoscope and applied directly to the target tissue. The tissue is frozen and then allowed to thaw, and repeated freeze-thaw cycles lead to tissue necrosis. One disadvantage of standard cryotherapy is the need to repeat bronchoscopy 3–7 days later to remove necrotic material.

A newer form of cryotherapy, 'cryoextraction', is performed with probes which have an improved joint between gas channel and probe in order to withstand much greater forces. The probe is applied to the tissue and the freeze cycle activated for 3–7 s (depending on the tissue composition). The bronchoscope is then removed with the cryoprobe and attached tumour tissue. The tissue is allowed to thaw once it is removed from the airway. This technique is undertaken using an endotracheal airway to facilitate repeated removal and reinsertion of the bronchoscope.

Indications

Cryotherapy—and, in particular, cryoextraction—is mainly indicated as a palliative measure in malignant airway obstruction. Cryoextraction can also be effectively applied to remove foreign objects and blood clots from the airways. There may be an indication for the treatment of low-grade malignant lesions such as adenoid cystic carcinoma and early cancer such as carcinoma in situ.⁴ The quality of specimens obtained using cryoextraction with absence of crush artefact has led to its use for endobronchial and transbronchial lung biopsy.

Complications

Cryotherapy appears to be safe in the treatment of malignant endobronchial obstruction. In case series,^{57–63} the complications observed were haemoptysis (4–10%), bronchospasm (4.5%), cardiac arrhythmia (11%) and death (1.3%).

One case series reported on cryoextraction for recanalisation (cryorecanalisation) with a 10% rate of significant bleeding (six patients) managed with conservative measures and APC; no deaths were reported in the series.⁶⁴ Another recent case series reported significant bleeding requiring APC or blocking devices in 8%.⁶⁵

Evidence

In the largest case series comprising 521 patients, cryotherapy appeared effective in the treatment of malignant endobronchial obstruction.⁵⁸ Technical success as judged by restoration of airway patency was 61% and improvement occurred in symptoms such as haemoptysis (61–76.4%), cough (69%) and dyspnoea (59–81%). One- and two-year survivals were 38.4% and 15.9%, respectively.⁵⁸ Another series of 225 patients showed airway patency restoration (complete or partial) in 91%.⁶⁵ A lot of the evidence base is from one centre which performed the procedure with a combination of rigid bronchoscopy and a flexible bronchoscope. The reviewers felt it was still important evidence that could be included in this guideline for flexible bronchoscopy, particularly as the technique can just as easily be performed by flexible bronchoscopy.

In one series where 57 patients with malignant tracheal bronchial obstruction were managed by bronchoscopy and cryoextraction, complete recanalisation was observed in 61% and partial restoration of patency in a further 22%.⁶⁴

Since cryoextraction produces immediate results (unlike conventional cryotherapy), it may be used for the management of acute tracheal or bronchial obstruction.^{64–66} Eighty-five per

cent of patients with endobronchial stenosis could be treated with immediate response. Application of this technique is possible at the lobar or segmental level.

In a recent multicentre trial, cryobiopsy sensitivity was 95% compared with forceps sensitivity of 85%.⁶⁷ The use of cryobiopsy for transbronchial lung biopsy has also been described. In a trial of 41 patients the mean specimen diameter was 15.11 mm with the cryoprobe compared with 5.82 mm with conventional forceps. Pneumothorax occurred in two patients.⁶⁷

Evidence statements

- ▶ Cryotherapy has an acceptable safety profile in the treatment of malignant endobronchial obstruction. (Evidence level 3)
- ▶ Cryotherapy is effective in the treatment of malignant endobronchial obstruction without critical airway narrowing. (Evidence level 3)
- ▶ Cryorecanalisation/cryoextraction is effective in the treatment of malignant endobronchial obstruction both with and without critical airway narrowing. (Evidence level 3)

Recommendations

- ▶ Cryotherapy may be considered for tumour debulking in patients without critical airway narrowing. (Grade D)
- ▶ Cryobiopsy may be considered for diagnostic endobronchial tissue sampling to provide large-volume specimens without crush artefact. (Grade B)
- ▶ Cryorecanalisation/cryoextraction may be considered for tumour debulking. (Grade D)

Photodynamic therapy (PDT)

Principles

PDT uses a systemic photosensitiser, most commonly a haematoxylin derivative, selectively retained and concentrated in tumour tissue to render the tumour sensitive to light of a given wavelength. The sensitised tumour is then illuminated by laser light of that wavelength, usually 630 Nm at the red end of the spectrum. In the presence of sensitiser and oxygen, laser light illumination causes tumour cell death by a complex pathway triggered by the release of singlet oxygen.

Technique

PDT requires a photosensitiser, a diode laser and a flexible light-guide, at the end of which is either a radial diffuser or a forward-projecting microlens. The photosensitiser most often used has been intravenous porfimer sodium administered in a dose of 200 mg/kg. The laser with its calibration device is a compact desktop instrument. Forty-eight hours after the administration of photosensitiser the tumour is illuminated by laser light using a flexible light-guide passed down the working channel of a standard flexible bronchoscope. The use of PDT lasers requires standard laser safety precautions, principally to address the risk of ocular damage. There are no thermal risks.

Indications

PDT has been used for the treatment of:

- ▶ Early central lung cancer, defined as visible endoscopically but not on imaging.
- ▶ The palliative treatment of malignancy causing endobronchial large airway obstruction.

Complications

Hematoporphyrin derivatives are taken up by skin, causing sensitivity to sunlight or bright direct light for up to 8 weeks. Protection of exposed areas is necessary, but indoor light is safe

and some light exposure is required to photobleach the sensitiser from the skin. In one series of nine patients there was one massive haemoptysis and one bronchopleural fistula.⁶⁸ Complications may arise from delayed necrosis of treated tissue.

Compared with electrocautery, more airway scarring and more subepithelial fibrosis were seen after treatment with PDT.⁴⁹

Organisation and cost

PDT requires the purchase or loan of a diode laser. Intravenous PDT sensitisers are expensive. Light-guides are reusable, being deployed inside a disposable plastic sheath.

Evidence

In the treatment of early central lung cancer, complete responses have been reported in 30–100% of patients and at least 80% in most series.^{69–71} Around a third of patients have required two treatments and a few have needed three treatments. Partial responders can be considered for other treatments including resection or radiotherapy if appropriate. Better responses have been reported for tumours 1 cm or less in diameter. Overall 5-year survival rates have been around 50%, cancer-specific survival up to 90%.

There are only a few series reporting the effect of PDT in palliating the endobronchial symptoms of advanced lung cancer, but it has been shown to be effective for palliation before or after other treatments. Moghissi *et al* reported experience of 100 cases, 82% of whom had been pretreated.⁷² Mean endoluminal obstruction (estimated bronchoscopically) fell from 86% to 17.5% with significant increases in forced expiratory volume in 1 s (FEV₁). All patients had symptomatic relief and 20% had a complete endoscopic response for 3–19 months. There was no treatment-related mortality in this series.

In a review of 12 papers comprising 636 patients with advanced lung cancer, almost all patients had some relief in cough and dyspnoea.⁷³ Comparisons with YAG laser treatment suggests more prolonged symptomatic relief with PDT,⁷⁴ but it has also been used in combination with YAG laser and with endobronchial radiotherapy, with some evidence of a better response to combined treatments.

Evidence statements

- ▶ PDT is effective in tumour debulking and palliation of symptoms in tracheobronchial obstruction from non-small cell lung carcinoma. (Evidence level 1–)
- ▶ PDT is effective in the palliation of advanced tracheobronchial lung cancer, although adverse events including haemoptysis can occur. (Evidence level 2+)
- ▶ PDT is effective in the curative treatment of early stage lung cancer. (Evidence level 2+)

Recommendations

- ▶ PDT may be considered for tumour debulking in patients without critical airway narrowing. (Grade D)
- ▶ PDT can be considered for the curative treatment of early central lung cancer, especially for tumours 1 cm or less in diameter and provided there is no imaging evidence of extrabronchial involvement. (Grade D)
- ▶ PDT can be considered for the curative treatment of recurrent lung cancer, for localised endobronchial disease in patients who are not fit for surgery or radical radiotherapy. (Grade D)

Good practice point

- ▶ The technique should be available for carefully selected patients on a regional basis, administered by physicians or

surgeons with a particular interest and expertise in lung cancer, bronchoscopy and airway management. (√)

Endobronchial brachytherapy

Principles

The word derives from the Greek 'Brachis' meaning 'close to'. It refers to the placement of radioactive sources within or alongside tumours, enabling an effective local dose to be administered but sparing surrounding tissues from the effects of radiation. The use of brachytherapy for lung tumours has been made possible by the development of high dose rate sources enabling treatment to be administered in minutes rather than hours. The technique is suitable for the relief of large airway obstruction and the relief of haemoptysis and other symptoms caused by endobronchial tumour. It can also be used with curative intent for tumours which are small enough to be encompassed by the limited field of radiation.

Technique

Most centres have used iridium-192, an artificially manufactured isotope. The treatment source consists of a series of iridium pellets housed in a stainless steel capsule approximately the size of a rice grain. It is welded to a drive cable and housed in a safe. A flexible bronchoscope is used to place an applicator (a blind-ending catheter) within or alongside an intraluminal tumour. The bronchoscope is then removed over a long guidewire, leaving the applicator in situ. The guidewire is removed and replaced by a radiodense graduated metal insert. A chest x-ray is taken and the treatment length planned using the insert and its relationship to the main carina to localise the area to be treated. The insert is then removed and the applicator connected to the safe. The radioactive source is then delivered by its drive cable to preplanned positions inside the applicator. The treatment length is determined by the number of positions selected and the diameter of the treatment field is determined by the dwell time at each position. Typically, in a sausage-shaped field, some 10×2 cm is administered. The treatment takes only a few minutes and is therefore suitable for outpatient or day case use. Most centres have used fractionated regimes, typically three fractions of 5–7.5 Gy,^{75 76} but the treatment is also effective as a single fraction of 15 Gy.⁷⁷

Indications

The technique is suitable for the primary and secondary palliation of symptoms caused by large airway obstruction including cough, shortness of breath, haemoptysis and obstructive collapse. It is effective for the treatment of endobronchial tumour and submucosal/peribronchial infiltration. It is not suitable for the treatment of extrinsic compression. It offers flexibility in a number of situations such as bilateral or multiple tumours, or in patients who have been pre-treated with other techniques including external beam radiotherapy. It may be considered for the attempted cure of early central lung cancer subject to accurate local staging to confirm that there has not been extrabronchial spread of tumour.

Complications

Some patients develop radiation bronchitis and occasionally stenosis. The principal serious risk is of massive haemoptysis, often occurring as a late complication in good responders, and more likely to occur with a higher local radiation dosage—that is, in patients who have also received external beam radiation either sequentially or concurrently.

Organisation and cost

The equipment is expensive to purchase but can also be used to treat other organ sites and is usually available in major radio-

therapy centres. It requires the availability of flexible bronchoscopy, preferably within the radiotherapy treatment area, and needs good collaboration between physician/endoscopist and clinical oncologist. Health economics comparisons are not straightforward, but it compares favourably with multifraction external beam treatments in terms of cost and patient convenience and avoids the side effects of external beam radiation, especially oesophagitis. It should be available to cancer networks as a treatment option for selected patients.

Evidence

Brachytherapy has been shown to be effective in the palliation of previously untreated inoperable lung cancer, relieving cough in 20–70% of patients, dyspnoea in 25–80% and haemoptysis in 70–90%.^{75 76 78 79} The relief of obstructive collapse has been reported in around 25% of patients.⁸⁰ Endoscopic evidence of tumour regression has been observed in most patients, with some complete responses.⁷⁵

Brachytherapy has also been reported to be effective in the palliation of previously treated lung cancer, with symptom relief and endoscopic improvement.^{77 80–82}

There are few comparative studies available, but Stout *et al* compared a single fraction of brachytherapy with fractionated palliative external beam radiotherapy, reporting comparable symptom relief but a slightly better duration of response for the external beam arm and also a slightly longer survival.⁸³

No survival benefit has been demonstrated for palliative treatments. Survival has been related, unsurprisingly, to performance status.

Brachytherapy has been used to treat radiologically-occult early-stage lung cancer.^{75 84} Complete endoscopic responses have been reported in 65–90% of patients, with partial responses in the remainder and 5-year survival of around 80%.

Brachytherapy has been shown to be safe and well tolerated, but massive haemoptysis has been reported in up to 7% of patients and is more likely with higher local dosage, combined or re-treatments, or following laser therapy.⁷⁷

Evidence statements

- ▶ Brachytherapy is effective in the palliation of inoperable lung cancer. (Evidence level 1)
- ▶ Brachytherapy is safe but massive haemoptysis has been reported in up to 7% of patients. (Evidence level 3)
- ▶ Brachytherapy may be used to treat early stage lung cancer (Evidence level 3)

Recommendations

- ▶ Brachytherapy should be considered for the palliation of haemoptysis or CAO in locally advanced central lung cancer. (Grade D)
- ▶ Brachytherapy should not be used first-line in preference to external beam radiotherapy for the palliation of lung cancer. (Grade C)
- ▶ Fractionated brachytherapy can be considered for the curative treatment of early central lung cancer, especially if performance or cardiorespiratory status precludes surgery or radical external beam radiotherapy. The success of brachytherapy for radical treatments requires accurate local staging to exclude extrabronchial tumour extension. (Grade C)

Tracheobronchial stents

Principles

Tracheal and bronchial stents can be used to maintain airway patency and integrity. Plastic (ie, silicone) stents^{85 86} and metal

stents are available. Silicone stents are deployed using rigid bronchoscopy under general anaesthesia. The majority of the published case series regarding outcomes and complications of stent deployment are for deployment by rigid bronchoscopy only.⁸⁷ Stent deployment using rigid bronchoscopy is not addressed in this guideline. A recent review offers further information.⁸⁸

Flexible bronchoscopy is an alternative to rigid bronchoscopy to deploy metallic airway stents. The current standard is the Self-Expanding Metallic Airway Stent (SEMAS), made from the alloy NITINOL (Nickel Titanium National Ordnance Laboratories).

Technique

SEMAS are used to treat airway stenosis or aerodigestive fistulae due to malignant disease. Their use is not advised in benign disease because of the high incidence of severe complications with prolonged use.

Before embarking upon a stenting procedure, a stent of the correct diameter, length and type must be chosen. The availability of modern multislice CT scans with multiplanar reformats has considerably facilitated this process, making it possible accurately to estimate the length and minimum diameter of the luminal stenosis and the diameter of the adjacent normal lumen. Where a main bronchus is extensively narrowed, the opposite main bronchus can be used to estimate the premorbid airway diameter. The length of the stent should be chosen to provide at least 0.5–1.0 cm of overlap at each end of the stenosed segment where possible. The diameter of the stent should be 1–2 mm greater than the estimated normal diameter of the airway. Stent sizing is usually 12–14 mm in diameter for main bronchi, 18–20 mm for the trachea, with lengths of 40 mm for the left main bronchus, 30–40 mm for the right main bronchus and 60–80 mm for the trachea. Where the lesion is exclusively extrabronchial, an uncovered stent is favoured because ventilation of side-branching bronchi can be maintained. For lesions with both extrinsic compression and endobronchial tumour, a stent incorporating a covering membrane ('covered stent') is favoured to prevent tumour in growth through the stent after deployment. A selection of stent sizes should be available prior to the procedure in case bronchoscopic inspection leads to a change of chosen stent size.

Some operators favour the insertion of an uncuffed endotracheal tube over the bronchoscope to protect the airway during the procedure. This may reduce trauma to the vocal cords from repeated bronchoscopic intubation and withdrawal during the procedure. After airway inspection a guidewire is introduced through the working channel of the bronchoscope and positioned beyond the distal extent of the lesion. The bronchoscope is then withdrawn leaving the guidewire in place. The bronchoscope is reintroduced next to the guidewire. The stent is placed over the guidewire and introduced. The distal end of the stent is advanced beyond the stenosed airway segment. The precise positioning of the proximal and distal ends of the stent can be checked either bronchoscopically or fluoroscopically. When these are satisfactory, the stent can be deployed.

A number of stent deployment devices are available. These all have the stent held compressed radially onto a delivery catheter and held down by a restraining mechanism which may be a silk thread or an external catheter. More recently, metallic carinal Y-stents have become available whose deployment is complex and better performed during rigid bronchoscopy.

Indications

SEMAS are used principally for the relief of CAO due to malignant disease. Other indications include malignant airway

fistulas and post-anastomosis bronchial strictures following lung transplantation.

Organisation

The expertise to deliver airway stenting should exist within each cancer network. It may be provided by thoracic surgeons or respiratory physicians, but should form part of multimodality treatment supervised by a properly constituted cancer multidisciplinary team. It is essential that the team performing the procedures should have appropriate expertise in managing airway complications, should they occur. Safe airway stenting requires the presence of at least two experienced practitioners, one to visualise the endobronchial appearances and one to deploy the stent.

Complications

The use of self-expanding metallic stents for the treatment of CAO is associated with a number of complications including stent malposition, migration or fracture, haemorrhage, mucus impaction, overgrowth by granulation tissue or tumour, infection, aerodigestive fistula formation and bronchospasm. Early stent-associated deaths have been reported due to complications such as hypoxia following stent migration, severe sepsis⁸⁹ and bronchospasm.⁹⁰ Complications may necessitate stent removal, which can be complex and hazardous where there has been a stent fracture. In benign airway conditions where life expectancy is greater, metallic stents are not recommended because of the longer-term risk of stent fracture.

Evidence

The absence of RCTs of airway stenting makes evaluation of its true effectiveness difficult. Nine case series (349 patients) have described the efficacy and safety of stent insertion by flexible bronchoscopy for malignant and benign airway conditions. SEMAS appear effective in improving breathlessness and cough.^{90–93} A visual increase in airway patency has been documented.⁹³ In a series of 40 patients with malignancy-associated CAO, the severe dyspnoea index improved in 34/39 patients within 24 h of stent insertion.⁹⁰

In CAO due to benign causes, stents improve symptoms. In a series of 40 patients this improvement was evident in stridor in 73% of cases, breathlessness in 71%, cough in 79% and in sputum clearance in 75%.⁹¹ In five series where a proportion of patients had lung function assessed before and after stent insertion,^{89 91–94} FEV₁, forced vital capacity (FVC) and airway resistance (where measured) improved.

In patients with acute respiratory failure due to malignant CAO requiring mechanical ventilation, stenting is associated with weaning from ventilatory support. In one series this was achieved in 14 of 26 patients with CAO, 21 of whom had malignancy.^{95 96} These case series data do not permit the identification of stenting as the cause of weaning success.

RCTs are needed to compare the addition of airway stenting to conventional anticancer treatments versus conventional treatment alone in patients with CAO due to malignancy.

Evidence statements

- ▶ Self-expanding metallic stents are effective in the treatment of malignant CAO following endobronchial debulking techniques. (Evidence level 3)
- ▶ Self expanding metallic stents are effective in the treatment of extrinsic malignant CAO. (Evidence level 3)

Recommendations

- ▶ The use of self-expanding metallic stents may be considered for the treatment of malignant CAO due to extrinsic disease. (Grade D)
- ▶ Self-expanding metallic stents may be used to maintain airway patency following endobronchial debulking techniques. (Grade D)
- ▶ Self-expanding metallic stents can be used to restore or maintain airway patency in conjunction with other treatments such as external beam radiotherapy. (Grade D)

Good practice points

- ▶ Patients require careful specialist follow-up after stent insertion. (✓)
- ▶ Stents should be used with caution in non-malignant disease because of their long-term complications. Self-expanding metallic stents may be difficult to remove following long-term placement. (✓)
- ▶ Self-expanding metallic stents should only be used in benign disease after all other therapeutic options have been exhausted. (✓)
- ▶ A risk-benefit assessment should be performed, incorporating immediate and long-term implications, before selecting any particular type of stent. (✓)

EMERGING APPLICATIONS FOR FLEXIBLE BRONCHOSCOPY

The following applications have been developed for use with the flexible bronchoscope but are yet to have established a clear place in routine practice.

Electromagnetic navigation bronchoscopy (ENB)

Principles

ENB is an image-guided localisation system to aid biopsy of lesions that are not visible endobronchially. It combines CT-generated virtual bronchoscopy and electromagnetic tracking of a steerable probe within the bronchial tree.

Technique

A multi-slice thin-section CT scan of the thorax is performed and used to create a 3-D virtual bronchoscopy. During virtual bronchoscopy, specific bronchial landmarks such as the main and segmental carinae are identified and the target lesion is marked. At bronchoscopy the patient lies in a magnetic field created by an electromagnetic board placed below the chest. A magnetic locatable probe, passed through the bronchoscope, is used to mark the same sites in the bronchial tree as were previously identified on virtual bronchoscopy. The two sets of data are then merged to co-register the CT data on the bronchoscopic spatial points. This allows the data from the virtual bronchoscopy to direct the bronchoscopic probe to the lesion. Once the desired location is reached, the locatable guide is exchanged for biopsy forceps or bronchial brushes and sampling is performed.

Indications

- ▶ Peripheral nodule sampling
- ▶ Targeted biopsy in patients with diffuse lung disease
- ▶ Mediastinal lymph node sampling
- ▶ Insertion of fiducial markers for radiotherapy
- ▶ Implantation of brachytherapy seeds or catheters
- ▶ Dye marker placement for surgical resection of peripheral mass

Complications

ENB appears to be safe, with pneumothorax as the most commonly reported complication. The rates of pneumothorax reported in three studies using ENB were 3.5–7.5%,^{97–99} which

are lower than reported rates of pneumothorax following CT-guided percutaneous needle biopsy.^{100–102} However, RCTs comparing the techniques have not been performed.

Evidence

The evidence comes from six case series^{97–99 103–105} with a total of 231 patients. In these studies a diagnostic rate of 59–80% was achieved. The results indicate that diagnostic accuracy is related to the size of the pulmonary opacity, with greater accuracy for masses >40 mm in diameter.

In a randomised study, Eberhardt *et al* achieved a higher diagnostic rate by combining ENB with radial EBUS than with ENB alone (88% vs 59%).¹⁰⁶ In a separate study they achieved a higher diagnostic rate using suction catheter aspiration (90%) compared with forceps biopsy (50%).¹⁰⁷

Studies using virtual bronchoscopy alone to guide peripheral lung biopsy have found similar diagnostic rates,^{108–110} and there is currently a lack of evidence that ENB provides additional sensitivity.

ENB appears to be a safe and effective but expensive modality for the sampling of peripheral lung lesions.

Recommendation

- ▶ Electromagnetic bronchoscopy may be considered for the biopsy of peripheral lesions or to guide TBNA for sampling mediastinal lymph nodes. (Grade D)

Valves in the treatment of emphysema

Principles

Patients with severe emphysema who are on maximal medical treatment are often very disabled. Treatment options other than lung transplantation and, in selected cases, lung volume reduction surgery are limited. This group of patients has significant morbidity with repeated hospitalisations and increased health-care utilisation. In the UK over 20% of patients with emphysema have severe disease, and in 2004 chronic obstructive pulmonary disease accounted for 1.4 million consultations with over 100 000 hospital admissions.

Endobronchial valves may be used in the treatment of patients with emphysema with severe hyperinflation. The valves are inserted into the target area of the lungs via flexible bronchoscopy under conscious sedation or general anaesthesia. Two different valves systems are available. The Zephyr valve is a one-way duck-billed valve and the intrabronchial valve (IBV) is an umbrella-like device. Both valves act by reducing gas inflow to the treated segment while allowing air and secretions to exit.

Technique

The procedure may be performed under conscious sedation or general anaesthesia. The insertion of an endotracheal tube at the beginning of the procedure is recommended. Under direct vision the size of the target airway is estimated. For the Zephyr valve, an appropriately-sized device on its catheter is inserted through the instrument channel of the bronchoscope and the valve is partly deployed. The valve is then wedged onto a carina in the target area to prevent distal or incorrect placement. Once appropriately positioned, the valve is fully deployed. Further valves are placed in order to achieve complete occlusion of the target lobe. Placement of the IBV is similar but requires accurate airway sizing with a calibrated balloon catheter.

Indications

- ▶ Heterogeneous (ie, >10% variation) in emphysematous destruction between adjacent lobes on CT scanning

- ▶ Moderate to severe airflow obstruction ($FEV_1 < 50\%$ predicted)
- ▶ Severe dyspnoea (MRC ≥ 2)
- ▶ Hyperinflation (total lung capacity $\geq 100\%$ predicted, residual volume $\geq 150\%$ predicted)
- ▶ Optimum treatment of chronic obstructive pulmonary disease for at least 6 weeks

Contraindications

- ▶ Carbon monoxide transfer factor $< 15\%$ predicted and $FEV_1 < 15\%$ predicted
- ▶ Oxygen tension on air < 6.0 kPa
- ▶ Production of purulent sputum more often than not ($> 50\%$ of days)
- ▶ Lung nodule requiring surgery

Evidence

The evidence consists of open-label cohort studies^{111–117} in 222 patients with severe emphysema and one randomised study has recently been published.¹¹⁸

Two devices have been used differently. The Zephyr valve has been used to produce atelectasis by unilateral treatment of a whole lobe. The IBV has been used in a strategy of airflow redirection by treating both upper lobes but leaving at least one sub-segment in each lobe open.¹¹⁹ Quantitative CT has shown that treatment of patients with emphysema with bronchial valves results in changes in regional volumes with a significant decrease in treated upper lobe volumes and a significant increase in the non-treated non-upper lobe volumes.¹²⁰

Treatment has been complicated by exacerbations and some pneumothoraces but is generally safe. In the randomised study there were eight deaths (2.7%) and the incidence of other key adverse events was distal pneumonia (0.5%), pneumothorax requiring an intercostal drain for > 7 days (1.4%) and respiratory failure (1.8%).¹¹⁸ There have been small improvements in lung function and variable improvements in quality of life depending on treatment strategy. The randomised study with Zephyr valves¹¹⁸ has shown only modest improvements in FEV_1 of about 5.8%. There were no consistent improvements in the 6 min walk test and quality of life measures.

The open-label study with the IBV demonstrated improvements in quality of life but no significant change in pulmonary function.¹¹⁹ However, the changes in subjective measures such as quality of life in an open-label study should be interpreted with caution. The place of endobronchial valves in patients with emphysema remains to be established.

Evidence statements

- ▶ Endobronchial valves in the treatment of emphysema appear to be safe in patients with severe disease. (Evidence level 1)
- ▶ Endobronchial valve insertion in patients with severe emphysema and hyperinflation leads to small improvements in lung function. (Evidence level 2–)

Recommendation

- ▶ Sufficient efficacy has not been demonstrated with endobronchial valves to recommend their use currently. However, they may be considered in the treatment of selected patients with severe emphysema and hyperinflation with heterogeneous disease in the absence of significant collateral ventilation or in those who have a complete fissure on CT scanning. (Grade B)

Good practice point

- ▶ Patients should be enrolled into clinical trials until more robust data of clinical benefit are available. (✓)

Other procedures in emphysema

A number of bronchoscopic procedures are being developed for emphysema that include airway stents (bypass procedure) in homogeneous emphysema, coils which lead to infolding of the lung, hydrofoam gel and steam instillation to induce localised fibrosis.

Bronchial thermoplasty for asthma

Principle

The prevalence of asthma is increasing and ranges from 10% to 13% in the UK. It is associated with a high admission rate of around 200 per 100 000 of the population per annum, and approximately 18% of patients in the UK have severe persistent asthma. Some symptoms are due to airflow obstruction as a direct result of airway smooth muscle contraction. Airway smooth muscle may also have a role in the pathogenesis of asthma by secreting proinflammatory cytokines and promoting airway remodelling. The goal of bronchial thermoplasty is to reduce airway smooth muscle.

Technique

The treatment is performed via flexible bronchoscopy under conscious sedation. Microwave energy is delivered to the bronchial wall via a flexible catheter from a radiofrequency generator. The treatment catheter is passed through the bronchoscope and is navigated to the distal target airway. A wire array at the distal end of the catheter is expanded and the radiofrequency generator activated. This heats the airway wall to about 65°C and selectively ablates the concentric smooth muscle. The airways are treated in a systematic manner from distal to proximal. The right lower lobe is treated first followed by the left lower lobe 3 weeks later, then the upper lobes.

Indications

Thermoplasty may be indicated in patients with severe persistent asthma receiving high-dose combination inhalers (> 1000 µg beclometasone equivalent) plus long-acting bronchodilators or long-term oral corticosteroids. The FEV_1 should be $> 50\%$ predicted.

Complications

Patients may experience post-procedure respiratory exacerbations. Limited long-term safety data for this procedure are available.

Evidence

The evidence base includes preliminary studies demonstrating feasibility and safety in 25 patients,¹²¹ 122 two randomised controlled studies in 146 patients and one randomised sham controlled study in 297 patients.^{123–125} The studies have consistently demonstrated a transient increase in asthma-related adverse events in the short term during the bronchoscopic treatment, but are associated with a significant reduction in adverse events, asthma-related symptoms and hospitalisations in the longer term. The AIR2 randomised sham controlled study demonstrated a 32% reduction in exacerbations and a decrease of $> 80\%$ in emergency room visits. There were improvements in quality of life and asthma control symptoms; the mean change in the Asthma Quality of Life Questionnaire (AQLQ) was 1.35 from baseline and 79% of patients had a clinically meaningful improvement in the AQLQ score. There was a reduction of 66% in days lost from work, school and other activities due to asthma.¹²⁵

However, despite some evidence for the use of thermoplasty in asthma, the studies are selective and the outcomes are only

positive in some aspects. This is a treatment which might be useful for some selected cases of difficult asthma. The final place of thermoplasty in cases of difficult asthma remains to be established.

Evidence statements

- ▶ Bronchial thermoplasty in patients with moderate to severe asthma has been associated with a short-term increase in asthma-related symptoms. (Evidence level 1)
- ▶ Bronchial thermoplasty in patients with moderate to severe asthma leads to a reduction in adverse events from 6 weeks after their final treatment. (Evidence level 1)
- ▶ Treatment with bronchial thermoplasty in patients with moderate to severe asthma has been shown to reduce the frequency of respiratory exacerbations, days lost from school or work due to asthma and to improve the quality of life. (Evidence level 1)

Recommendation

- ▶ Bronchial thermoplasty is a possible treatment option in selected patients with severe persistent asthma already on maximal therapy, although its place in the treatment of asthma remains to be established. (Grade A)

Good practice point

- ▶ Long-term safety and efficacy remains unclear. Hence, treatment should be limited to a few specialist centres in carefully selected patients. Longer term follow-up of treated patients is recommended. (√)

CONCLUSION

This guideline provides an evidence-based overview of advanced diagnostic and therapeutic techniques, some of which are widely available and some of which are only available in specialist centres. It is clear that TBNA and EBUS are becoming standard practice in all regions. Tumour ablation is not routinely available via flexible bronchoscopy in all regions, and there are insufficient trainees who feel competent to undertake these procedures at the end of their training. There is therefore a need to identify those centres which provide hands-on training and to increase the availability of that training.

In this rapidly developing field, new techniques and more evidence are going to become available so it is planned to review this guideline in 2015. There is also a need provide the evidence for patients, other practitioners and commissioners of the benefits of these techniques in the UK, so it will be important for centres using advanced bronchoscopy techniques to keep careful records and undertake audit.

Not all techniques described here will be used in all centres or even every region. Some centres may continue, for example, to refer all patients for stenting or tumour ablation to surgical units. However, there is a need for all practitioners to be aware of what is available and to know when to consider referring patients for procedures they do not undertake themselves.

Competing interests None.

Provenance and peer review Not commissioned; internal and external peer review undertaken by the Standards of Care Committee of the British Thoracic Society.

REFERENCES

1. **Toma TP**, Geddes DM, Shah PL. Brave new world for interventional bronchoscopy. *Thorax* 2005;**60**:180–1.
2. **Du Rand IA**, Lewis RA. BTS bronchoscopy training survey 2009. *Thorax* 2009;**64**:A159–66.
3. **Ernst A**, Silvestri GA, Johnstone D; American College of Chest Physicians. Interventional pulmonary procedures: guidelines from the American College of Chest Physicians. *Chest* 2003;**123**:1693–717.
4. **Bolliger CT**, Mathur PN, Beams JF, *et al*; European Respiratory Society/American Thoracic Society. ERS/ATS statement on interventional pulmonology. *European Respiratory Society/American Thoracic Society. Eur Respir J* 2002;**19**:356–73.
5. **Kemp SV**, El Batrawy SH, Harrison RN, *et al*. Learning curves for endobronchial ultrasound using cusum analysis. *Thorax* 2010;**65**:534–8.
6. **Tournoy KG**, Annema JT, Krasnik M, *et al*. Endoscopic and endobronchial ultrasonography according to the proposed lymph node map definition in the seventh edition of the tumor, node, metastasis classification for lung cancer. *J Thorac Oncol* 2009;**4**:1576–84.
7. **Holtz JE**, Kuschner WG, Gould MK. Accuracy of transbronchial needle aspiration for mediastinal staging of non-small cell lung cancer: a meta-analysis. *Thorax* 2005;**60**:949–55.
8. **Detterbeck FC**, Jantz MA, Wallace M, *et al*; American College of Chest Physicians. Invasive mediastinal staging of lung cancer: ACCP evidence-based clinical practice guidelines (2nd edition). *Chest* 2007;**132**(3 Suppl):202S–205S.
9. **Diacon AH**, Schuurmans MM, Theron J, *et al*. Transbronchial needle aspirates: how many passes per target site? *Eur Respir J* 2007;**29**:112–16.
10. **Chin R Jr**, McCain TW, Lucia MA, *et al*. Transbronchial needle aspiration in diagnosing and staging lung cancer: how many aspirates are needed? *Am J Respir Crit Care Med* 2002;**166**:377–81.
11. **Bilaceroglu S**, Perim K, Günel O, *et al*. Combining transbronchial aspiration with endobronchial and transbronchial biopsy in sarcoidosis. *Monaldi Arch Chest Dis* 1999;**54**:217–23.
12. **Trisolini R**, Tinelli C, Cancellieri A, *et al*. Transbronchial needle aspiration in sarcoidosis: yield and predictors of a positive aspirate. *J Thorac Cardiovasc Surg* 2008;**135**:837–42.
13. **Herth FJ**, Eberhardt R, Vilmann P, *et al*. Real-time endobronchial ultrasound guided transbronchial needle aspiration for sampling mediastinal lymph nodes. *Thorax* 2006;**61**:795–8.
14. **Gu P**, Zhao YZ, Jiang LY, *et al*. Endobronchial ultrasound-guided transbronchial needle aspiration for staging of lung cancer: a systematic review and meta-analysis. *Eur J Cancer* 2009;**45**:1389–96.
15. **Adams K**, Shah PL, Edmonds L, *et al*. Test performance of endobronchial ultrasound and transbronchial needle aspiration biopsy for mediastinal staging in patients with lung cancer: systematic review and meta-analysis. *Thorax* 2009;**64**:757–62.
16. **Varela-Lema L**, Fernandez-Villar A, Ruano-Ravina A. Effectiveness and safety of endobronchial ultrasound-transbronchial needle aspiration: a systematic review. *Eur Respir J* 2009;**33**:1156–64.
17. **Tolozza EM**, Harpole L, Detterbeck F, *et al*. Invasive staging of non-small cell lung cancer: a review of the current evidence. *Chest* 2003;**123**(1 Suppl):157S–66S.
18. **Tournoy KG**, Rintoul RC, van Meerbeek JP, *et al*. EBUS-TBNA for the diagnosis of central parenchymal lung lesions not visible at routine bronchoscopy. *Lung Cancer* 2009;**63**:45–9.
19. **Nakajima T**, Yasufuku K, Fujiwara T, *et al*. Endobronchial ultrasound-guided transbronchial needle aspiration for the diagnosis of intrapulmonary lesions. *J Thorac Oncol* 2008;**3**:985–8.
20. **Kennedy MP**, Jimenez CA, Bruzzi JF, *et al*. Endobronchial ultrasound-guided transbronchial needle aspiration in the diagnosis of lymphoma. *Thorax* 2008;**63**:360–5.
21. **Wong M**, Yasufuku K, Nakajima T, *et al*. Endobronchial ultrasound: new insight for the diagnosis of sarcoidosis. *Eur Respir J* 2007;**29**:1182–6.
22. **Okamoto M**, Saka H, Kitagawa C, *et al*. Real-time endobronchial ultrasound-guided transbronchial needle aspiration is useful for diagnosing sarcoidosis. *Respirology* 2007;**12**:863–8.
23. **Garwood S**, Judson MA, Silvestri G, *et al*. Endobronchial ultrasound for the diagnosis of pulmonary sarcoidosis. *Chest* 2007;**132**:1298–304.
24. **Tournoy KG**, Bolly A, Aerts JG, *et al*. The value of endoscopic ultrasound after bronchoscopy to diagnose thoracic sarcoidosis. *Eur Respir J* 2010;**35**:1329–35.
25. **Cavaliere S**, Venuta F, Foccoli P, *et al*. Endoscopic treatment of malignant airway obstructions in 2008 patients. *Chest* 1996;**110**:1536–42.
26. **Sutedja T**, Bolliger CT. Endobronchial electrocautery and argon plasma coagulation. In: *Progress in Respiratory Research*. Basel: Karger, 2000:120–32.
27. **Van Boxem TJ**, Venmans BJ, Schramel FM, *et al*. Radiographically occult lung cancer treated with fiberoptic bronchoscopic electrocautery: a pilot study of a simple and inexpensive technique. *Eur Respir J* 1998;**11**:169–72.
28. **Marel M**, Pekarek Z, Spasova I, *et al*. Management of benign stenoses of the large airways in the university hospital in Prague, Czech Republic, in 1998–2003. *Respiration* 2005;**72**:622–8.
29. **Sutedja TG**, van Boxem TJ, Schramel FM, *et al*. Endobronchial electrocautery is an excellent alternative for Nd:YAG laser to treat airway tumors. *J Bronchol* 1997;**4**:101–5.
30. **Hooper RG**, Jackson FN. Endobronchial electrocautery. *Chest* 1985;**87**:712–14.
31. **Hooper RG**, Jackson FN. Endobronchial electrocautery. *Chest* 1988;**94**:595–8.
32. **Ho AM**, Wan S, Karmakar MK. Flooding with carbon dioxide prevents airway fire induced by diathermy during open tracheostomy. *J Trauma* 2007;**63**:228–31.
33. **Horinouchi H**, Miyazawa T, Takada K, *et al*. Safety study of endobronchial electrocautery for tracheobronchial lesions: multicenter prospective study. *J Bronchol* 2008;**15**:228–32.
34. **Medicines and Healthcare products Regulatory Agency (MHRA)**. *Guidelines for the Perioperative Management of Patients with Implantable Pacemakers or Implantable Cardioverter Defibrillators, where the use of Surgical Diathermy*

- Electrocautery is Anticipated*, 2006. <http://www.mhra.gov.uk/home/groups/dts-bi/documents/websitesresources/con2023451.pdf> (accessed 13 Feb 2010).
35. **Sutedja G**, van Kralingen K, Schramel FM, *et al*. Fiberoptic bronchoscopic electrosurgery under local anaesthesia for rapid palliation in patients with central airway malignancies: a preliminary report. *Thorax* 1994;**49**:1243–6.
 36. **Homasson JP**, Roden S, Angebault M, *et al*. [Treatment of bronchial tumors with high-frequency thermocoagulation. Preliminary studies] (In French). *Rev Pneumol Clin* 1995;**51**:77–81.
 37. **Gerasin VA**, Shafirovsky BB. Endobronchial electrosurgery. *Chest* 1988;**93**:270–4.
 38. **De la Cruz LI**, Pereira A, Krieger BP. Use of endobronchial electrocautery for the palliation of airway obstruction due to metastases from nonpulmonary malignancies. *J Bronchol* 2006;**13**:124–7.
 39. **Morice RC**, Ece T, Ece F, *et al*. Endobronchial argon plasma coagulation for treatment of hemoptysis and neoplastic airway obstruction. *Chest* 2001;**119**:781–7.
 40. **Reichle G**, Freitag L, Kullmann H-J, *et al*. Argon plasma coagulation in bronchology: a new method—alternative or complementary? *J Bronchol* 2000;**7**:109–17.
 41. **Okada S**, Yamauchi H, Ishimori S, *et al*. Endoscopic surgery with a flexible bronchoscope and argon plasma coagulation for tracheobronchial tumors. *J Thorac Cardiovasc Surg* 2001;**121**:180–2.
 42. **Crosta C**, Spaggiari L, De Stefano A, *et al*. Endoscopic argon plasma coagulation for palliative treatment of malignant airway obstructions: early results in 47 cases. *Lung Cancer* 2001;**33**:75–80.
 43. **Keller CA**, Hinerman R, Singh A, *et al*. The use of endoscopic argon plasma coagulation in airway complications after solid organ transplantation. *Chest* 2001;**119**:1968–75.
 44. **Reddy C**, Majid A, Michaud G, *et al*. Gas embolism following bronchoscopic argon plasma coagulation: a case series. *Chest* 2008;**134**:1066–9.
 45. **Cavaliere S**, Foccoli P, Farina PL. Nd:YAG laser bronchoscopy. A five-year experience with 1,396 applications in 1,000 patients. *Chest* 1988;**94**:15–21.
 46. **Brutinel WM**, Cortese DA, McDougall JC. A two-year experience with the neodymium-YAG laser in endobronchial obstruction. *Chest* 1987;**91**:159–65.
 47. **Katic MR**, Burick AJ, Lucchino DB. Experiences with laser bronchoscopy. *Pa Med* 1991;**94**:24–7.
 48. **Hetzel MR**, Nixon C, Edmondstone WM, *et al*. Laser therapy in 100 tracheobronchial tumours. *Thorax* 1985;**40**:341–5.
 49. **van Boxem AJ**, Westerga J, Venmans BJ, *et al*. Photodynamic therapy, Nd-YAG laser and electrocautery for treating early-stage intraluminal cancer: which to choose? *Lung Cancer* 2001;**31**:31–6.
 50. **Dumon JF**, Reboud E, Garbe L. Treatment of tracheobronchial lesions by laser photoresection. *Chest* 1982;**81**:278–84.
 51. **Parr GV**, Unger M, Trout RG, *et al*. One hundred neodymium-YAG laser ablations of obstructing tracheal neoplasms. *Ann Thorac Surg* 1984;**38**:374–81.
 52. **Jung SS**, Weiman TJ. Endobronchial Nd:YAG laser surgery. *J Ky Med Assoc* 1989;**87**:227–9.
 53. **Chan AL**, Tharratt RS, Siefkin AD, *et al*. Nd:YAG laser bronchoscopy. Rigid or fiberoptic mode? *Chest* 1990;**98**:271–5.
 54. **Beamis JF Jr**, Vergos K, Rebeiz EE, *et al*. Endoscopic laser therapy for obstructing tracheobronchial lesions. *Ann Otol Rhinol Laryngol* 1991;**100**:413–19.
 55. **Coulter TD**, Mehta AC. The heat is on: impact of endobronchial electrosurgery on the need for Nd-YAG laser photoresection. *Chest* 2000;**118**:516–21.
 56. **Boxem T**, Muller M, Venmans B, *et al*. Nd-YAG laser vs bronchoscopic electrocautery for palliation of symptomatic airway obstruction: a cost-effectiveness study. *Chest* 1999;**116**:1108–12.
 57. **Homasson JP**, Renault P, Angebault M. Bronchoscopic cryotherapy for airway strictures caused by tumors. *Chest* 1986;**90**:159–64.
 58. **Maiwand MO**, Evans JM, Beeson JE. The application of cryosurgery in the treatment of lung cancer. *Cryobiology* 2004;**48**:55–61.
 59. **Asimakopoulos G**, Beeson J, Evans J, *et al*. Cryosurgery for malignant endobronchial tumors: analysis of outcome. *Chest* 2005;**127**:2007–14.
 60. **Marasso A**, Gallo E, Massaglia GM, *et al*. Cryosurgery in bronchoscopic treatment of tracheobronchial stenosis. Indications, limits, personal experience. *Chest* 1993;**103**:472–4.
 61. **Maiwand MO**. Cryotherapy for advanced carcinoma of the trachea and bronchi. *BMJ (Clin Res Ed)* 1986;**293**:181–2.
 62. **Mathur PN**, Wolf KM, Busk MF, *et al*. Fiberoptic bronchoscopic cryotherapy in the management of tracheobronchial obstruction. *Chest* 1996;**110**:718–23.
 63. **Vergnon JM**, Schmitt T, Alamartine E, *et al*. Initial combined cryotherapy and irradiation for unresectable non-small cell lung cancer; preliminary results. *Chest* 1992;**102**:1436–40.
 64. **Hetzel M**, Hetzel J, Schumann C, *et al*. Cryorecanalization: a new approach for the immediate management of acute airway obstruction. *J Thorac Cardiovasc Surg* 2004;**127**:1427–31.
 65. **Schumann C**, Lepper PM, Barth TF, *et al*. Successful immediate cryorecanalization of a simultaneous high-grade tracheal and bronchial stenosis as rare manifestations of bronchial-associated lymphoid tissue lymphoma. *J Thorac Cardiovasc Surg* 2009;**137**:e17–19.
 66. **Schirrmeister H**, Hetzel M, Hetzel J, *et al*. Challenging manifestations of malignancies: Case 3. Fibrinous tracheitis: an uncommon manifestation of Hodgkin's lymphoma. *J Clin Oncol* 2004;**22**:3642–3.
 67. **Babiak A**, Hetzel J, Krishna G, *et al*. Transbronchial cryobiopsy: a new tool for lung biopsies. *Respiration* 2009;**78**:203–8.
 68. **Magro CM**, Abbas AE, Ross P Jr. The application of photodynamic therapy in the treatment of metastatic endobronchial disease. *Lasers Surg Med* 2006;**38**:376–83.
 69. **Moghissi K**, Dixon K, Thorpe JA, *et al*. Photodynamic therapy (PDT) in early central lung cancer: a treatment option for patients ineligible for surgical resection. *Thorax* 2007;**62**:391–5.
 70. **Edell ES**, Cortese DA. Photodynamic therapy in the management of early superficial squamous cell carcinoma as an alternative to surgical resection. *Chest* 1992;**102**:1319–22.
 71. **Jitsuo U**, Tsutsui H, Honda H, *et al*. Photodynamic therapy for lung cancers based on novel photodynamic diagnosis using talaporfin sodium (NPe6) and autofluorescence bronchoscopy. *Lung Cancer* 2007;**58**:317–23.
 72. **Moghissi K**, Dixon K, Stringer M, *et al*. The place of bronchoscopic photodynamic therapy in advanced unresectable lung cancer: experience of 100 cases. *Eur J Cardiothorac Surg* 1999;**15**:1–6.
 73. **Moghissi K**, Dixon K. Is bronchoscopic photodynamic therapy a therapeutic option in lung cancer? *Eur Respir J* 2003;**22**:535–41.
 74. **Diaz-Jimenez JP**, Martínez-Ballarín JE, Lluell A, *et al*. Efficacy and safety of photodynamic therapy versus Nd-YAG laser resection in NSCLC with airway obstruction. *Eur Respir J* 1999;**14**:800–5.
 75. **Ozkok S**, Karakoyun-Celik O, Goksel T, *et al*. High dose rate endobronchial brachytherapy in the management of lung cancer: response and toxicity evaluation in 158 patients. *Lung Cancer* 2008;**62**:326–33.
 76. **Kelly JF**, Delclos ME, Morice RC, *et al*. High-dose-rate endobronchial brachytherapy effectively palliates symptoms due to airway tumors: the 10-year M. D. Anderson cancer center experience. *Int J Radiat Oncol Biol Phys* 2000;**48**:697–702.
 77. **Gollins SW**, Ryder WD, Burt PA, *et al*. Massive haemoptysis death and other morbidity associated with high dose rate intraluminal radiotherapy for carcinoma of the bronchus. *Radiation Oncol* 1996;**39**:105–16.
 78. **Anacak Y**, Mogulkoc N, Ozkok S, *et al*. High dose rate endobronchial brachytherapy in combination with external beam radiotherapy for stage III non-small cell lung cancer. *Lung Cancer* 2001;**34**:253–9.
 79. **Gejerman G**, Mullokanov EA, Bagiele E, *et al*. Endobronchial brachytherapy and external-beam radiotherapy in patients with endobronchial obstruction and extrabronchial extension. *Brachytherapy* 2002;**1**:204–10.
 80. **Hernandez P**, Gursahaney A, Roman T, *et al*. High dose rate brachytherapy for the local control of endobronchial carcinoma following external irradiation. *Thorax* 1996;**51**:354–8.
 81. **Lo TC**, Girshovich L, Healey GA, *et al*. Low dose rate versus high dose rate intraluminal brachytherapy for malignant endobronchial tumors. *Radiation Oncol* 1995;**35**:193–7.
 82. **Raju PI**, Roy T, McDonald RD, *et al*. IR-192, low dose rate endobronchial brachytherapy in the treatment of malignant airway obstruction. *Int J Radiat Oncol Biol Phys* 1993;**27**:677–80.
 83. **Stout R**, Barber P, Burt P, *et al*. Clinical and quality of life outcomes in the first United Kingdom randomized trial of endobronchial brachytherapy (intraluminal radiotherapy) vs external beam radiotherapy in the palliative treatment of inoperable non-small cell lung cancer. *Radiation Oncol* 2000;**56**:323–7.
 84. **Fuwa N**, Matsumoto A, Kamata M, *et al*. External irradiation and intraluminal irradiation using middle-dose-rate iridium in patients with roentgenographically occult lung cancer. *Int J Radiat Oncol Biol Phys* 2001;**49**:965–71.
 85. **Montgomery WW**. T-tube tracheal stent. *Arch Otolaryngol* 1965;**82**:320–1.
 86. **Dumon JF**. A dedicated tracheobronchial stent. *Chest* 1990;**97**:328–32.
 87. **Madden BP**, Park JE, Sheth A. Medium-term follow-up after deployment of ultraflex expandable metallic stents to manage endobronchial pathology. *Ann Thorac Surg* 2004;**78**:1898–902.
 88. **Ibrahim E**. Bronchial stents. *Ann Thorac Med* 2006;**1**:92–7.
 89. **Hautmann H**, Bauer M, Pfeifer KJ, *et al*. Flexible bronchoscopy: a safe method for metal stent implantation in bronchial disease. *Ann Thorac Surg* 2000;**69**:398–401.
 90. **Monnier P**, Mudry A, Stanzel F, *et al*. The use of the covered Wallstent for the palliative treatment of inoperable tracheobronchial cancers. A prospective, multicenter study. *Chest* 1996;**110**:1161–8.
 91. **Chan AL**, Juarez MM, Allen RP, *et al*. Do airway metallic stents for benign lesions confer too costly a benefit? *BMC Pulm Med* 2008;**8**:7.
 92. **Lonchyna VA**, Arcidi JM Jr, Garrity ER Jr, *et al*. Refractory post-transplant airway strictures: successful management with wire stents. *Eur J Cardiothorac Surg* 1999;**15**:842–50.
 93. **Miyazawa T**, Yamakido M, Ikeda S, *et al*. Implantation of Ultraflex nitinol stents in malignant tracheobronchial stenoses. *Chest* 2000;**118**:959–65.
 94. **Hsu LH**, Liu CC, Lin CY, *et al*. Self-expandable metallic tracheobronchial stent insertion and endobronchial electrocautery with flexible bronchoscopy: preliminary results at a cancer center. *J Formos Med Assoc* 2002;**101**:399–405.
 95. **Lin SM**, Lin TY, Chou CL, *et al*. Metallic stent and flexible bronchoscopy without fluoroscopy for acute respiratory failure. *Eur Respir J* 2008;**31**:1019–23.
 96. **Dasgupta A**, Dolmatch BL, Abi-Saleh WJ, *et al*. Self-expandable metallic airway stent insertion employing flexible bronchoscopy: preliminary results. *Chest* 1998;**114**:106–9.
 97. **Gildea TR**, Mazzone PJ, Karnak D, *et al*. Electromagnetic navigation diagnostic bronchoscopy: a prospective study. *Am J Respir Crit Care Med* 2006;**174**:982–9.
 98. **Eberhardt R**, Anantham D, Herth F, *et al*. Electromagnetic navigation diagnostic bronchoscopy in peripheral lung lesions. *Chest* 2007;**131**:1800–5.
 99. **Makris D**, Gourgoulis K. Electromagnetic navigation diagnostic bronchoscopy and transbronchial biopsy. *Chest* 2008;**133**:829–30.

100. **Li H**, Boiselle PM, Shepard JO, *et al*. Diagnostic accuracy and safety of CT-guided percutaneous needle aspiration biopsy of the lung: comparison of small and large pulmonary nodules. *AJR Am J Roentgenol* 1996;**167**:105–9.
101. **Laurent F**, Michel P, Latrabe V, *et al*. Pneumothoraces and chest tube placement after CT-guided transthoracic lung biopsy using a coaxial technique: incidence and risk factors. *AJR Am J Roentgenol* 1999;**172**:1049–53.
102. **Khan MF**, Straub R, Moghaddam SR, *et al*. Variables affecting the risk of pneumothorax and intrapulmonary hemorrhage in CT-guided transthoracic biopsy. *Eur Radiol* 2008;**18**:1356–63.
103. **Schwarz Y**, Greif J, Becker HD, *et al*. Real-time electromagnetic navigation bronchoscopy to peripheral lung lesions using overlaid CT images: the first human study. *Chest* 2006;**129**:988–94.
104. **Lamprecht B**, Porsch P, Pirich C, *et al*. Electromagnetic navigation bronchoscopy in combination with PET-CT and rapid on-site cytopathologic examination for diagnosis of peripheral lung lesions. *Lung* 2009;**187**:55–9.
105. **Bertoletti L**, Robert A, Cottier M, *et al*. Accuracy and feasibility of electromagnetic navigated bronchoscopy under nitrous oxide sedation for pulmonary peripheral opacities: an outpatient study. *Respiration* 2009;**78**:293–300.
106. **Eberhardt R**, Anantham D, Ernst A, *et al*. Multimodality bronchoscopic diagnosis of peripheral lung lesions: a randomized controlled trial. *Am J Respir Crit Care Med* 2007;**176**:36–41.
107. **Eberhardt R**, Morgan RK, Ernst A, *et al*. Comparison of suction catheter versus forceps biopsy for sampling of solitary pulmonary nodules guided by electromagnetic navigational bronchoscopy. *Respiration* 2010;**79**:54–60.
108. **Asano F**, Matsuno Y, Shinagawa N, *et al*. A virtual bronchoscopic navigation system for pulmonary peripheral lesions. *Chest* 2006;**130**:559–66.
109. **Tachihara M**, Ishida T, Kanazawa K, *et al*. A virtual bronchoscopic navigation system under x-ray fluoroscopy for transbronchial diagnosis of small peripheral pulmonary lesions. *Lung Cancer* 2007;**57**:322–7.
110. **Shinagawa N**, Yamazaki K, Onodera Y, *et al*. Factors related to diagnostic sensitivity using an ultrathin bronchoscope under CT guidance. *Chest* 2007;**131**:549–53.
111. **Yim AP**, Hwong TM, Lee TW, *et al*. Early results of endoscopic lung volume reduction for emphysema. *J Thorac Cardiovasc Surg* 2004;**127**:1564–73.
112. **Wan IY**, Toma TP, Geddes DM, *et al*. Bronchoscopic lung volume reduction for end-stage emphysema: report on the first 98 patients. *Chest* 2006;**129**:518–26.
113. **Hopkinson NS**, Toma TP, Hansell DM, *et al*. Effect of bronchoscopic lung volume reduction on dynamic hyperinflation and exercise in emphysema. *Am J Respir Crit Care Med* 2005;**171**:453–60.
114. **Venuta F**, de Giacomo T, Rendina EA, *et al*. Bronchoscopic lung-volume reduction with one-way valves in patients with heterogenous emphysema. *Ann Thorac Surg* 2005;**79**:411–17.
115. **Toma TP**, Hopkinson NS, Hillier J, *et al*. Bronchoscopic volume reduction with valve implants in patients with severe emphysema. *Lancet* 2003;**361**:931–3.
116. **Fraioli F**, Calabrese FA, Venuta F, *et al*. MDCT assessment of lung volume in patients undergoing bronchial stenting for treatment of pulmonary emphysema: correlation with respiratory tests and personal experience (In Italian). *Radiol Med* 2006;**111**:749–58.
117. **de Oliveira HG**, Macedo-Neto AV, John AB, *et al*. Transbronchoscopic pulmonary emphysema treatment: 1-month to 24-month endoscopic follow-up. *Chest* 2006;**130**:190–9.
118. **Sciurba FC**, Ernst A, Herth FJ, *et al*; VENT Study Research Group. A randomized study of endobronchial valves for advanced emphysema. *N Engl J Med* 2010;**363**:1233–44.
119. **Wood DE**, McKenna RJ Jr, Yusen RD, *et al*. A multicenter trial of an intrabronchial valve for treatment of severe emphysema. *J Thorac Cardiovasc Surg* 2007;**133**:65–73.e2.
120. **Coxson HO**, Nasute Fauerbach PV, Storness-Bliss C, *et al*. Computed tomography assessment of lung volume changes after bronchial valve treatment. *Eur Respir J* 2008;**32**:1443–50.
121. **Miller JD**, Cox G, Vincic L, *et al*. A prospective feasibility study of bronchial thermoplasty in the human airway. *Chest* 2005;**127**:1999–2006.
122. **Cox G**, Miller JD, McWilliams A, *et al*. Bronchial thermoplasty for asthma. *Am J Respir Crit Care Med* 2006;**173**:965–9.
123. **Cox G**, Thomson NC, Rubin AS, *et al*; AIR Trial Study Group. Asthma control during the year after bronchial thermoplasty. *N Engl J Med* 2007;**356**:1327–37.
124. **Pavord ID**, Cox G, Thomson NC, *et al*. Safety and efficacy of bronchial thermoplasty in symptomatic, severe asthma. *Am J Respir Crit Care Med* 2007;**176**:1185–91.
125. **Castro M**, Rubin AS, Laviolette M, *et al*; AIR2 Trial Study Group. Effectiveness and safety of bronchial thermoplasty in the treatment of severe asthma: a multicenter, randomized, double-blind, sham-controlled clinical trial. *Am J Respir Crit Care Med* 2010;**181**:116–24.
126. **Wahidi MM**, Herth FJ, Ernst A. State of the art: interventional pulmonology. *Chest* 2007;**131**:261–74.
127. **Celebioglu B**, Gurkan OU, Erdogan S, *et al*. High dose rate endobronchial brachytherapy effectively palliates symptoms due to inoperable lung cancer. *Jpn J Clin Oncol* 2002;**32**:443–8.
128. **Walsh DA**, Maiwand MO, Nath AR, *et al*. Bronchoscopic cryotherapy for advanced bronchial carcinoma. *Thorax* 1990;**45**:509–13.
129. **Maiwand MO**, Homasson JP. Cryotherapy for tracheobronchial disorders. *Clin Chest Med* 1995;**16**:427–43.
130. **Venuta F**, Rendina EA, De Giacomo T, *et al*. Nd:YAG laser resection of lung cancer invading the airway as a bridge to surgery and palliative treatment. *Ann Thorac Surg* 2002;**74**:995–8.
131. **Petrou M**, Kaplan D, Goldstraw P. Bronchoscopic diathermy resection and stent insertion: a cost effective treatment for tracheobronchial obstruction. *Thorax* 1993;**48**:1156–9.

APPENDIX 1 Committee membership and declared conflict of interest

Contributor	Sections contributed	Conflict of interest
Professor RA Lewis Chairman of the British Thoracic Society Interventional Bronchoscopy Guideline Group. Consultant Respiratory Physician with a special interest in lung cancer Worcestershire Royal Hospital Worcester	Development of the Guideline Electromagnetic Navigation Bronchoscopy Photodynamic Therapy Endobronchial Valves Diathermy Evidence tables	Professor Lewis has been in receipt of loan and prototype equipment from Olympus Ltd. Professor Lewis has no financial interest in Olympus Ltd. He is a faculty member of an interventional bronchoscopy course that is sponsored by Olympus, Erbe, Cook Medical, Superdimension, Taewoong medical, Alveolus & Emphysis. Prof Lewis has no financial interest in any of these companies and there is no conflict of interest in relation to the guideline.
Dr IA Du Rand Specialist Registrar in Respiratory Medicine West Midlands Deanery Completing MSc Oxford University in Evidence Based Medicine Dr PV Barber Consultant Respiratory Physician with a special interest in lung cancer University hospital of South Manchester, Manchester	Development of the Guideline Developed website for on-line appraisal General Interventional Bronchoscopy Evidence tables Appendix 3 Photodynamic Therapy Brachytherapy Evidence tables Appendix 3	None Dr Barber has used diode laser equipment loaned by Axcan Ltd. He has no financial interest in Axcan Ltd.
Dr J Goldring Specialist Registrar in Respiratory Medicine London deanery	General Interventional Bronchoscopy Diathermy Evidence tables	None
Dr S Mandal Specialist Registrar in Respiratory Medicine London deanery	General Interventional Bronchoscopy Diathermy Evidence tables	None

Continued

Continued

Contributor	Sections contributed	Conflict of interest
Dr M Munavvar Consultant Respiratory Physician with a special interest in lung cancer Lancashire Teaching Hospitals Preston	Endobronchial Ultrasound Argon Plasma Coagulation Evidence tables	Dr M Munavvar has been involved in prototype evaluation of interventional bronchoscopy/thoracoscopy related equipment for Olympus, Boston Scientific, Cook and Spiration. He organises Interventional Bronchoscopy/Thoracoscopy and Basic Bronchoscopy courses, which are sponsored by numerous companies including Olympus, ERBE, Wolf, Sonosite, Rocket, UK Medical, Nucleotron, Pentax, Fujinon, Conmed, Cook, Spiration and others. Dr Munavvar has no financial interest in any of these companies and there is no conflict of interest in relation to the guidelines.
Dr RC Rintoul Consultant Respiratory Physician with a special interest in lung cancer Papworth Hospital Papworth Everard Cambridge CB23 3RE	Endobronchial Ultrasound Electromagnetic navigation Laser therapy Cryotherapy General Interventional bronchoscopy Evidence tables	Dr Rintoul is in receipt of loan equipment from Olympus Ltd and Hitachi Pentax and Papworth Hospital acts as a reference centre for the technique of EBUS-TBNA. Olympus Ltd has provided educational grants to support courses about EBUS. Dr Rintoul has no financial interest in either Olympus Ltd or Hitachi Pentax.
Dr PL Shah Chairman of the BTS Interventional Pulmonology SAG Consultant Respiratory Physician with a special interest in lung cancer Royal Brompton Hospital and the Chelsea and Westminster Hospital, London	Laser Cryotherapy Endobronchial valves Thermoplasty Brachytherapy Photodynamic therapy Evidence tables	Dr PL Shah is a principle investigator for a number of clinical trials and the host institutions for the trials (Royal Brompton Hospital and the Chelsea & Westminster Hospital have been reimbursed for clinical trial expenses by Asthmatx, Boehringer Ingelheim, Broncus, Olympus & PneumRx. He is the course director for an interventional bronchoscopy course which has been sponsored by Olympus, Erbe, Cook Medical, Superdimension, Taewoong medical, Alveolus & Emphysis. Dr Shah has no financial interest in any commercial entity whose interests are in any way connected with this guideline.
Dr S Singh Secretary of the BTS Interventional Pulmonology SAG Consultant Respiratory and Intensive Care Physician Chelsea and Westminster Hospital, London	Stenting Thermoplasty Evidence tables	Dr S Singh is a co investigator for interventional bronchoscopy trials in bronchial thermoplasty and lung coils. He is a faculty member of an interventional bronchoscopy course that is, sponsored by Olympus, Erbe, Cook Medical, Superdimension, Taewoong medical, Alveolus & Emphysis. He has previously received Speaker fees from Cook Medical. Dr Singh has no financial interest in any company associated with this guideline.
Dr MG Slade Consultant Respiratory Physician with a special interest in lung cancer Papworth Hospital Papworth Everard Cambridge CB23 3RE	Argon plasma coagulation Stenting Evidence tables Appendix 2	Dr Slade is clinical director of thoracic services at Papworth Hospital, which is or has been in receipt of loan equipment from Olympus UK Ltd and Hitachi Medical Ltd. Olympus UK, Pentax UK, Boston Scientific UK, Erbe Medical UK, Richard Wolf UK and Storz UK have sponsored educational courses on interventional pulmonology run by Dr Slade in Oxford and Cambridge. Dr Slade has no financial interest in any commercial entity whose interests are in any way connected with this guideline.
Dr A Woolley Consultant Respiratory Physician Worcestershire Royal Hospital Worcester	Electromagnetic Navigation Bronchoscopy Evidence tables	None

The assistance of the following colleagues is gratefully acknowledged:
Nicholas Smith BA(Hons) MSc, Information Support Librarian.
Emma Gibbs, Senior Library Assistant.
Laura Birchley, Library Assistant.
Rowlands Library, Worcestershire Royal Hospital.

APPENDIX 2 A step-by-step practical guide for performing transbronchial needle aspiration (TBNA)

Initial considerations

TBNA requires very few additional resources to implement, and is therefore readily available to all practitioners. Bronchoscopists have, however, frequently found that 'real-world' results do not equal those in the published literature. This guide is intended to help shorten the learning curve.

TBNA is best viewed as a team effort. Optimal results depend upon

- (i) Familiarity with the needle for both the bronchoscopist and the assisting staff.
- (ii) Collaboration with colleagues in cytopathology to ensure optimal specimen preparation.
- (iii) Careful pre-procedure discussion with a radiologist to ensure that the bronchoscopist knows where the targets are endobronchially.

The needle

There are several different TBNA needles available and choice between them is clearly a matter of personal preference and cost. It is recommended that demonstration needles are obtained of different types. Needles with a clear plastic outer sheath have the advantage that the aspirated material can be viewed during sampling, which helps the operator to know that the sample will be adequate. The whole team should practise with the chosen needle so that everyone knows what instructions will be given for advancing and retracting the needle, how and when to apply and release suction, and so on.

Tuition

There are a number of courses available on advanced techniques in bronchoscopy, which offer hands-on training in TBNA technique. It is strongly recommended that a new operator attends such a course, ideally together with bronchoscopy assisting staff.

The procedure

- (i) The procedure described is for lymph node sampling. TBNA can also be used to sample extrabronchial tumour, or to take specimens from deep within necrotic lesions.
- (ii) Target lymph nodes are identified from prior CT or PET scanning. If the procedure is being performed for lung cancer staging, a plan is made to sample the highest-station nodes first (i.e., N3 before N2 before N1).
- (iii) The bronchoscopy is begun as usual. Once the bronchoscope is within the trachea, lymph node sampling is performed before any other inspection or sampling. If possible suctioning within the airways is avoided, lest any exfoliated malignant cells enter the working channel and contaminate the TBNA sample. If the view is obscured by mucus or blood, the injection of a small quantity of saline is used to clear the optic.
- (iv) The bronchoscope is positioned over the first target site, and the needle sheath advanced through the working channel. Approximately 5 mm of needle sheath is allowed to protrude from the distal end of the channel.
- (v) The bronchoscope is flexed so that the tip of the needle sheath lies against the airway wall, between the cartilaginous rings, and directed towards the target.
- (vi) The needle sheath is anchored within the working channel by one of two methods: operators with large hands may be able to use the little finger to apply gentle pressure to the sheath against the wall of the working channel, while still directing the

bronchoscope. Others may prefer to ask an assistant to anchor the needle sheath. An advantage for the operator of anchoring the needle oneself is that subtle tactile feedback occurs as the sheath tip moves up and down the airway, 'bumping over' the cartilage rings. This may facilitate precise, correct positioning of the sheath tip between the rings.

(vii) The assistant is then asked to advance the needle, using some agreed instruction (eg, 'needle out'). If the needle is of a type that has a reasonably stiff wire running down it, and if the tip of the sheath is correctly positioned between the airway cartilages, the needle will often pass directly through the airway wall. This is known as the 'Hub against the wall' method. If the needle does not penetrate the airway and instead causes the sheath and bronchoscope to recoil, the operator can advance the bronchoscope, with the needle sheath still anchored within the working channel, to attempt penetration with the 'Piggy back' method.

(viii) Once the needle has passed through the airway wall, it may be necessary to advance the needle sheath, while carefully withdrawing the bronchoscope, so that more of the needle sheath is visible before sampling begins. Otherwise, as the needle sheath is drawn back to begin the cycle of to-and-fro motion through the lymph node, the airway wall may simply recoil forwards towards the bronchoscope, obscuring the view, before any relative motion between the needle and the lymph node has occurred.

(ix) The bronchoscopist then asks that suction be applied to the needle.

(x) The bronchoscopist then begins to-and-fro motion of the needle sheath, and observes carefully the motion of the needle as it enters the airway wall. It is important to be able to observe definite motion in and out, though care should be taken not to withdraw the needle completely from the airway wall. This takes considerable practice.

(xi) During the sampling process it is helpful if an assistant holds the bronchoscope stationary at the nose or mouth.

(xii) With some experience it is possible for the operator to know whether a lymph node is being successfully sampled. If it is, then gooe material, looking a little like

pink toothpaste or raspberry ripple ice-cream, is seen entering the needle sheath. If the needle appears to be well-positioned, and satisfactory passes are being performed, but no such aspirate is obtained, it is worth slowly withdrawing the needle and then advancing it rapidly in a jabbing motion. This is because some lymph nodes have a relatively tough capsule that deforms steadily as the needle is advanced, without permitting penetration. A jabbing action can overcome this effect and allow the needle to enter the node, which then yields "goo" as above.

(xiii) Once a satisfactory specimen is obtained, the needle is withdrawn by the assistant, in response to a clear and previously agreed instruction from the operator. The needle sheath is withdrawn and the specimen prepared by the assistant.

(xiv) The way that specimens are prepared will depend upon the preference of the local cytopathologist. The options are direct smears, air-dried or fixed with cytological fixative, or both; or simple flushing of the sample into liquid, which may be either saline, cytological fixative or media suitable for RNA extraction or flow cytometry. The best results, in the author's experience, are always obtained by giving the cytopathology department what it wants.

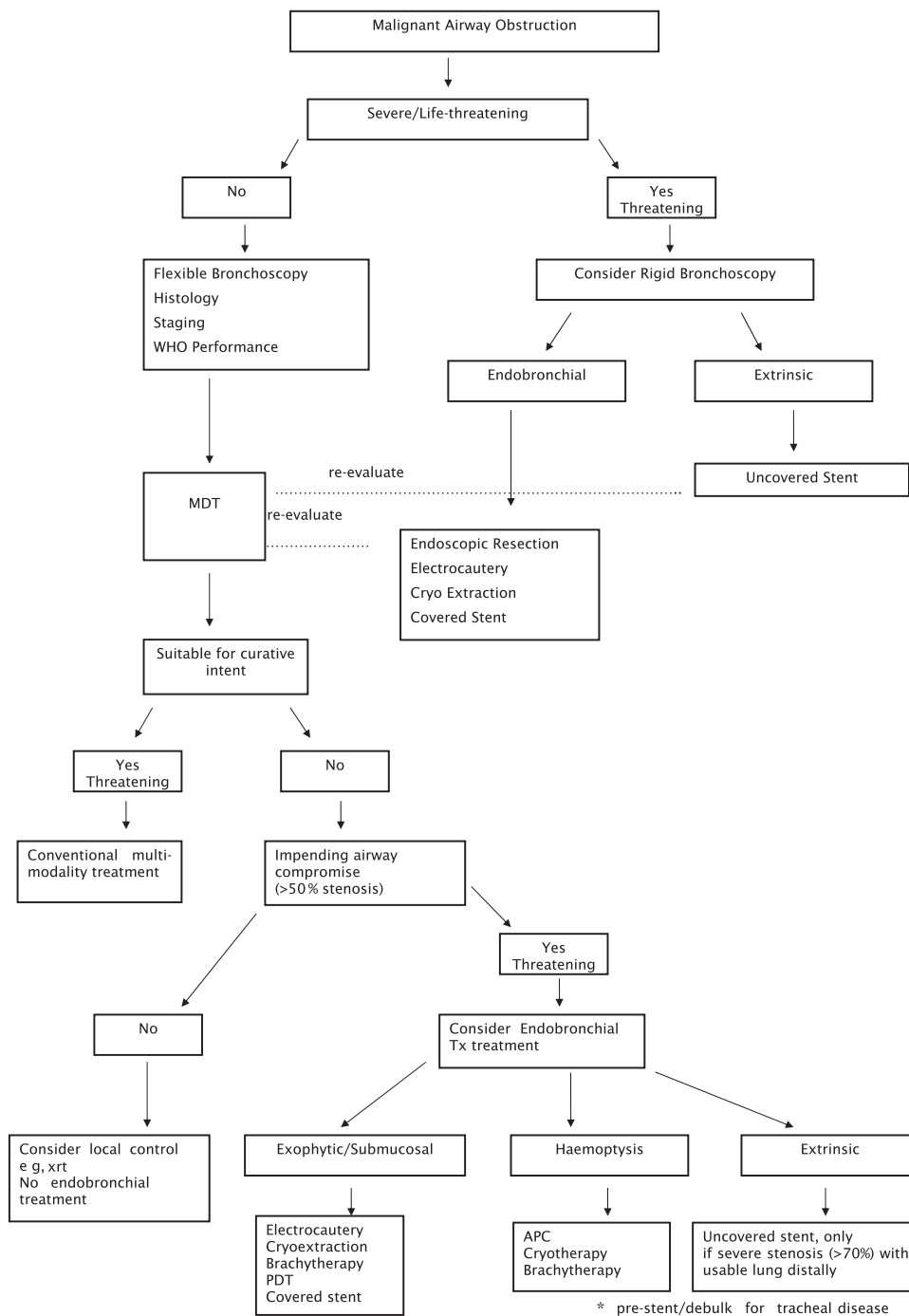
(xv) Further samples are then taken from the same lymph node station, before moving on to further, lower-stage sites. It is recommended that up to 5 passes are obtained through each node.

Golden rules

There are a few rules that will help to avoid complications and promote success.

- (i) The needle should never be advanced unless the tip of its sheath is clearly visible, otherwise the needle may perforate the working channel.
- (ii) Always sample the highest-station nodes first.
- (iii) Don't give up if the first few nodes sampled give non-diagnostic results. The learning curve for TBNA is not flat.
- (iv) Aim for large (>2 cm short axis) nodes for your first few procedures.

APPENDIX 3
An example of a malignant airway obstruction flow
diagram (local facilities may determine the
approach used)



Thorax: first published as 10.1136/thoraxjnl-2011-200713 on 10 October 2011. Downloaded from <http://thorax.bmj.com/> on 12 July 2018 by guest. Protected by copyright.

	Time to onset of action	Contra-indications	Advantages	Disadvantages	Effectiveness to palliate symptoms (% patients)	Effectiveness to open airway (% patients)	Complications
PDT	Within 48 h, ³ often much quicker	Tracheal disease requires pre-stent or debulk Porphyria Allergy to haematoporphyrin	Effective palliative measure for endobronchial airway obstruction.	Delayed onset of action. Debulking often required after palliative treatment Skin photosensitivity for 6–8 weeks	100% ¹²⁶	80% ³	Skin Burn if not protected Initial airway oedema/obstruction Late stricture Occasional major bleeding Radiation bronchitis Late stenosis Late massive haemoptysis
Brachytherapy	Gradual over days or weeks, occasionally months	Prior high-dose radiation or thermal laser Tracheal disease may require pre-stent or debulk	Long-term palliation of symptomatic endobronchial malignancy	Requires specialised equipment and radiotherapist collaboration	69–90% ^{81 126 127}	78–85% ^{81 126 127}	Major bleeding Radiation bronchitis Late stenosis Late massive haemoptysis
Original Cryotherapy	1–2 weeks		Can be used to remove foreign objects or mucus plugs	Multiple bronchoscopies required	70–93% ^{60 126 128 129}	77–79% ^{60 126 128 129}	Bleeding Initial hyperaemia of tumour, with temporary increase in airway obstruction. Bleeding following tumour extraction
Cryo-extraction	Immediate effect		Effective palliation of central airway obstruction.	Requires specialist equipment	>90%	83–91%	Bleeding following tumour extraction
Thermal Laser	Immediate	If exclusive extrinsic airway compression	Rapid therapeutic effect. Extensive experience worldwide	Not well established as a flexible bronchoscopy technique; poorly tolerated with conscious sedation. Difficult to treat upper lobe lesions	63–94% ^{45 56 130}	>90% in trachea ³ 60–70% for more distal lesions ^{3 45 56 130}	Smoke Haemorrhage Hypoxia Airway perforation Airway fire risk with >40% FiO ₂
Diathermy/ Electrocautery	Immediate effect	Caution with pacemaker	Inexpensive Good safety profile	Time-consuming probe in contact with tissue, needs frequent cleaning	70–97% ^{35 56 131}	88% ^{35 56 131}	Airway fire Contact burns Airway perforation
APC	Immediate effect	Caution with pacemaker	Effective in haemoptysis and for larger areas of superficial cancer	Ineffective for major debulking	100% in haemoptysis ⁴²	91% ^{42 126}	Bleeding Fire Late stenosis

APPENDIX 4

Evidence Tables

Available on-line on the BTS Website and at <http://thorax.bmjgroup.com>

APPENDIX 5

List of Stakeholders

Name of College/Society

Royal College of Physicians
Royal College of Physicians, Edinburgh
Royal College of Surgeons of England
Royal College of Surgeons of Edinburgh
Royal College of Physicians and Surgeons of Glasgow

Royal College of Anaesthetists
British Geriatrics Society
Society for Acute Medicine
TSANZ
Endoscopy UK
NICE
Royal College of General Practitioners
Royal College of Nursing
Royal college of Pathologists
British Society of Clinical Cytology
British Oncological Association
Royal College of Radiologists
Society for Cardiothoracic Surgery in GB and Ireland
KeyMed Olympus Pentax—commercial stakeholders contacted only upon completion of the guideline for comments